PULLIAM, Viktoriya (id #6945, dob: 12/06/1989)

Encounter Date: 01/04/2024

Patient

Name	PULLIAM, VIKTORIYA (34yo, F) ID# 6945	**Appt. Date/Time**	01/04/2024 03:15PM
DOB	12/06/1989	**Service Dept.**	WPI-Gillette
Provider	JOHN L. MANSELL, MD		

Prescription: CVS|CAREMARK - Member is eligible. details

Chief Complaint

arm numbness and heaviness

Patient's Care Team

Primary Care Provider: AMY HAWK APRN: 501 S BURMA AVE, GILLETTE, WY 82716, Ph (307) 688-3535, Fax (307) 688-7916 NPI: 1104345404

Patient's Pharmacies

WALGREENS DRUG STORE #07928 (ERX): 2000 S DOUGLAS HWY, GILLETTE, WY 82718, Ph (307) 682-4517, Fax (307) 682-4563

Vitals

Ht: 5 ft 6 in 01/04/2024 03:19 pm	**HR:** 75 01/04/2024 03:19 pm	**RR:** 16 01/04/2024 03:19 pm
BP: 133/94 sitting R arm 01/04/2024 03:19 pm	**T:** 97.3 F° temporal artery 01/04/2024 03:20 pm	**O2Sat:** 99% Room Air at Rest 01/04/2024 03:20 pm

Allergies

Reviewed Allergies

PENICILLINS

Medications

Reviewed Medications

ibuprofen 800 mg tablet 10/16/23 filled
TAKE 1 TABLET BY MOUTH THREE TIMES DAILY WITH FOOD OR MILK AS NEEDED

Problems

Reviewed Problems
No known problems

Family History

Reviewed Family History

Unspecified Relation	- Family history of alcoholism - Grandfather
	- Diabetes mellitus - Grandmother
	- Family history of cancer - Grandmother- ovarian , brain ca
Brother	- Family history of substance abuse - Illegal Drug Abuse
Father	- Heart disease
	- Hypertensive disorder

PULLIAM, Viktoriya (id #6945, dob: 12/06/1989)

Social History

Reviewed Social History
Public Health and Travel
Have you been to an area known to be high risk for COVID-19?: No
Substance Use
Do you or have you ever smoked tobacco?: Former smoker
Do you or have you ever used smokeless tobacco?: Never used smokeless tobacco
How much tobacco do you chew?: none
What was the date of your most recent tobacco screening?: 09/23/2021
Do you use any illicit or recreational drugs?: No
What is your level of caffeine consumption?: Moderate
Education and Occupation
Are you currently employed?: Yes
Other
Live alone or with others?: with others
Gender Identity and LGBTQ Identity
Gender identity: Choose not to disclose
Assigned sex at birth: Choose not to disclose
Sexual orientation: Choose not to disclose

Surgical History

Reviewed Surgical History
- Hysterectomy

GYN History

Reviewed GYN History

Obstetric History

Reviewed Obstetric History

Past Medical History

Reviewed Past Medical History
Anxiety Disorder: **Y**
Head Trauma/Injury: **Y**
Headaches: **Y**

Screening

None recorded.

HPI

This is a pleasant 34-year-old lady who had previously undergone and anterior cervical discectomy and fusion in November 2022 who presents today with two months of progressively worsening numbness in her ulnar forearms with episodes of her arms feeling heavy and "dead".

At times her legs will also feel heavy and the bottoms of her feet will be on fire.

She denies any change in bladder or rectal control or unintentional weight loss.
The pain in her forearms with the heaviness tends to be paroxysmal and is not links to any particular activity or triggered by any position.

I spent 20 minutes with this patient which consisted of chart review, patient interview and examination, documentation and coordination of care all on the same day. Time is the basis of this E & M CPT code.

ROS

Constitutional: Constitutional: no fever or night sweats.

ENMT: Nose: no frequent nosebleeds. Mouth/Throat: no bleeding gums.

Neurologic: Neurologic: no seizures or loss of consciousness and **weakness** and **numbness**.

Psychiatric: Psych: no hallucinations or suicidal thoughts.

Hematologic/Lymphatic: Hematologic/Lymphatic no bruising or excessive bleeding.

Allergic/Immunologic: Allergy/Immunologic: no itching or hives.

Physical Exam

Chaperone: Chaperone: present.

Constitutional: General Appearance: healthy-appearing, well-nourished, and well-developed. Level of Distress: NAD. Ambulation: ambulating normally.

Psychiatric: Insight: good judgement. Mental Status: normal mood and affect and active and alert. Orientation: to time, place, and person. Memory: recent memory normal and remote memory normal.

PULLIAM, Viktoriya (id #6945, dob: 12/06/1989)

Head: Head: normocephalic and atraumatic.

Eyes: Lids and Conjunctivae: non-injected and no discharge. Pupils: PERRLA. EOM: EOMI. Sclerae: non-icteric.

ENMT: Nose: no lesions on external nose or nasal discharge.

Lungs: Respiratory effort: no dyspnea.

Cardiovascular: Pulses including femoral / pedal: radial left +2 and right +2.

Neurologic: Cranial Nerves: grossly intact. Sensation: grossly intact (**in her upper extremities other than slightly decreased sensation in distal ulnar forearms**). Reflexes: **trace brachioradialis and triceps bilaterally, 1+ biceps bilaterally, negative Tinels at the cubital tunnels and wrist flexion crease bilaterally. !+ patellar and Achilles bilaterally.**. Lumbar / Lumbosacral Spine negative left straight leg raise and right straight leg raise; **negative Lhermitte's**. ATHENA Cervical Spine Strength **Symmetric and normal strength deltoids, triceps, biceps, wrist flexion and extension and grip.**.

Skin: Inspection and palpation: good turgor and no jaundice.

Back: Thoracolumbar Appearance: **erect posture with negative Spurlings in neutral and tilted postures.**.

Assessment / Plan

With bilateral arm heaviness and similar complaints in her lower extremities I spoke with Dr. Schubert (her surgeon) who agreed that new imaging was warranted.

1. Cervical post-laminectomy syndrome
M96.1: Postlaminectomy syndrome, not elsewhere classified

- MRI, CERVICAL SPINE, W/O CONTRAST

  Height (ft.): 5 ft 6 in

  Place of service: OFFICE
  Procedure code: 72141
- XR, CERVICAL SPINE, 4 OR 5 VIEW

  Views (X-RAY, CERVICAL SPINE): AP, Lateral, Flexion, Extension, odontoid

  Place of service: OFFICE
  Procedure code: 72050

  Authorization: Aetna (POS) | NOTREQUIRED | Not Required for 72050

Return to Office

Patient will return to the office as needed.

Encounter Sign-Off

Encounter signed-off by John L. Mansell, MD, 01/04/2024.

Encounter performed and documented by John L. Mansell, MD
Encounter reviewed & signed by John L. Mansell, MD on 01/04/2024 at 03:55 PM

PULLIAM, Viktoriya (id #6945, dob: 12/06/1989)

Encounter Date: 10/20/2021

Patient

Name	PULLIAM, VIKTORIYA (31yo, F) ID# 6945	**Appt. Date/Time**	10/20/2021 03:00PM
DOB	12/06/1989	**Service Dept.**	WPI-Gillette
Provider	JOHN L. MANSELL, MD		
Insurance	Med Primary: *SELF PAY* Prescription: CVS|CAREMARK - Member is eligible. details		

Chief Complaint

neck and shoulder pain

Patient's Care Team

Referring Provider: JUSTIN MERRYMAN DC: 201 W LAKEWAY RD STE 211, GILLETTE, WY 82718, Ph (307) 217-2323, Fax (307) 228-2184 NPI: 1790227866
Primary Care Provider: AMY HAWK APRN: 501 S BURMA AVE, GILLETTE, WY 82716, Ph (307) 688-3535, Fax (307) 688-7916

Patient's Pharmacies

WALGREENS DRUG STORE #07928 (ERX): 2000 S DOUGLAS HWY, GILLETTE, WY 82718, Ph (307) 682-4517, Fax (307) 682-4563

Vitals

10/20/2021 03:14 pm

Ht: 5 ft 6 in

Allergies

Reviewed Allergies

PENICILLINS

Medications

Reviewed Medications

acyclovir 5 % topical ointment APPLY TOPICALLY TO THE AFFECTED AREA 6 TIMES DAILY FOR 7 DAYS	07/23/21	filled
cabergoline 0.5 mg tablet TAKE 1 TABLET BY MOUTH EVERY DAY	08/18/21	filled
escitalopram 20 mg tablet TAKE 1 TABLET BY MOUTH EVERY DAY	10/11/21	filled
methylPREDNISolone 4 mg tablets in a dose pack FOLLOW PACKAGE DIRECTIONS	07/23/21	filled
OXcarbazepine 300 mg tablet TAKE 1 TO 2 TABLETS BY MOUTH AT BEDTIME	08/12/21	filled
prednisoLONE acetate 1 % eye drops,suspension SHAKE LIQUID AND INSTILL 1 DROP IN BOTH EYES THREE TIMES DAILY	07/23/21	filled
valACYclovir 1 gram tablet TAKE 1 TABLET BY MOUTH THREE TIMES DAILY X 7 DAYS FOR OUTBREAKS/PAINFUL LESION	07/23/21	filled

Problems

PULLIAM, Viktoriya (id #6945, dob: 12/06/1989)

Reviewed Problems
No known problems

Family History

Reviewed Family History

Unspecified Relation	- Family history of alcoholism - Grandfather
	- Diabetes mellitus - Grandmother
	- Family history of cancer - Grandmother- ovarian , brain ca
Brother	- Family history of substance abuse - Illegal Drug Abuse
Father	- Heart disease
	- Hypertensive disorder

Social History

Reviewed Social History
Other
Live alone or with others?: with others
Education and Occupation
Are you currently employed?: Yes
Substance Use
Do you or have you ever smoked tobacco?: Former smoker
Do you or have you ever used smokeless tobacco?: Never used smokeless tobacco
How much tobacco do you chew?: none
What was the date of your most recent tobacco screening?: 09/23/2021
Do you use any illicit or recreational drugs?: No
What is your level of caffeine consumption?: Moderate
Public Health and Travel
Have you been to an area known to be high risk for COVID-19?: No
Gender Identity and LGBTQ Identity
Gender identity: Choose not to disclose
Assigned sex at birth: Choose not to disclose
Sexual orientation: Choose not to disclose

Surgical History

Reviewed Surgical History

GYN History

Reviewed GYN History

Obstetric History

Reviewed Obstetric History

Past Medical History

Reviewed Past Medical History
Anxiety Disorder: **Y**
Head Trauma/Injury: **Y**
Headaches: **Y**

Screening

None recorded.

HPI

This is a record of a Zoom meeting with the patient's lawyer who wanted me to review her records from treatment prior to her arrival in Gillette. We have a consent to discuss her medical details with her attorney.

During this call he informed me that she had two automobile accidents about nine months apart and would send me details about them so I could review the details of each accident for further analysis.

We exchanged contact details.

I explained the severity of her cervical spinal stenosis and the need to have a surgical evaluation sooner rather than later.

ROS

PULLIAM, Viktoriya (id #6945, dob: 12/06/1989)

None recorded.

Physical Exam

None recorded.

Assessment / Plan

This was a meeting to discuss her case with her attorney.

1. Spinal stenosis in cervical region
M48.02: Spinal stenosis, cervical region

Return to Office
Patient will return to the office as needed.

Encounter Sign-Off
Encounter signed-off by John L. Mansell, MD, 10/20/2021.

Encounter performed and documented by John L. Mansell, MD
Encounter reviewed & signed by John L. Mansell, MD on 10/20/2021 at 08:40 PM

PULLIAM, Viktoriya (id #6945, dob: 12/06/1989)

Encounter Date: 09/23/2021

Patient

Name	PULLIAM, VIKTORIYA (31yo, F) ID# 6945	**Appt. Date/Time**	09/23/2021 01:00PM
DOB	12/06/1989	**Service Dept.**	WPI-Gillette
Provider	JOHN L. MANSELL, MD		
Insurance	Med Primary: *SELF PAY* Prescription: CVS|CAREMARK - Member is eligible. details		

Chief Complaint

neck and shoulder pain with diffuse left arm tingling

Patient's Care Team

Referring Provider: JUSTIN MERRYMAN DC: 201 W LAKEWAY RD STE 211, GILLETTE, WY 82718, Ph (307) 217-2323, Fax (307) 228-2184 NPI: 1790227866
Primary Care Provider: AMY HAWK APRN: 501 S BURMA AVE, GILLETTE, WY 82716, Ph (307) 688-3535, Fax (307) 688-7916

Patient's Pharmacies

WALGREENS DRUG STORE #07928 (ERX): 2000 S DOUGLAS HWY, GILLETTE, WY 82718, Ph (307) 682-4517, Fax (307) 682-4563

Vitals

09/23/2021 01:10 pm

Ht: 5 ft 6 in **Pain Scale:** 4

Allergies

Reviewed Allergies

PENICILLINS

Medications

Reviewed Medications

acyclovir 5 % topical ointment 07/23/21 filled
APPLY TOPICALLY TO THE AFFECTED AREA 6 TIMES DAILY FOR 7 DAYS

cabergoline 0.5 mg tablet 08/18/21 filled
TAKE 1 TABLET BY MOUTH EVERY DAY

escitalopram 20 mg tablet 08/22/21 filled
TAKE 1 TABLET BY MOUTH EVERY DAY

methylPREDNISolone 4 mg tablets in a dose pack 07/23/21 filled
FOLLOW PACKAGE DIRECTIONS

OXcarbazepine 300 mg tablet 08/12/21 filled
TAKE 1 TO 2 TABLETS BY MOUTH AT BEDTIME

prednisoLONE acetate 1 % eye drops,suspension 07/23/21 filled
SHAKE LIQUID AND INSTILL 1 DROP IN BOTH EYES THREE TIMES DAILY

valACYclovir 1 gram tablet 07/23/21 filled
TAKE 1 TABLET BY MOUTH THREE TIMES DAILY X 7 DAYS FOR OUTBREAKS/PAINFUL LESION

Problems

PULLIAM, Viktoriya (id #6945, dob: 12/06/1989)

Reviewed Problems
No known problems

Family History

Reviewed Family History

Unspecified Relation	- Family history of alcoholism - Grandfather
	- Diabetes mellitus - Grandmother
	- Family history of cancer - Grandmother- ovarian , brain ca
Brother	- Family history of substance abuse - Illegal Drug Abuse
Father	- Heart disease
	- Hypertensive disorder

Social History

Reviewed Social History
Other
Live alone or with others?: with others
Education and Occupation
Are you currently employed?: Yes
Substance Use
Do you or have you ever smoked tobacco?: Former smoker
Do you or have you ever used smokeless tobacco?: Never used smokeless tobacco
How much tobacco do you chew?: none
What was the date of your most recent tobacco screening?: 09/23/2021
Do you use any illicit or recreational drugs?: No
What is your level of caffeine consumption?: Moderate
Public Health and Travel
Have you been to an area known to be high risk for COVID-19?: No
Gender Identity and LGBTQ Identity
Gender identity: Choose not to disclose
Assigned sex at birth: Choose not to disclose
Sexual orientation: Choose not to disclose

Surgical History

Reviewed Surgical History

GYN History

Reviewed GYN History

Obstetric History

Reviewed Obstetric History

Past Medical History

Reviewed Past Medical History
Anxiety Disorder: **Y**
Head Trauma/Injury: **Y**
Headaches: **Y**

Screening

None recorded.

HPI

This is a pleasant 31 year old lady with neck and shoulder pain with left arm tingling who had undergone a previous cervical spine MRI about 18 months ago which showed severe cervical spinal stenosis at the C5-6 level with an only 5 mm AP dimension.

Since that scan her pain has gotten worse but she denies any changes in lower extremity strength or sensation or bladder or rectal control.

Because her pain has gotten worse I recommended repeating her imaging as her central canal stenosis has probably progressed as well.

We also discussed my concern that the severity of her stenosis might make her more vulnerable to more severe injury if she were to fall or be involved in a car accident. She seemed to understand this as well.

I spent 20 minutes with this patient which consisted of chart review, patient interview and examination,

PULLIAM, Viktoriya (id #6945, dob: 12/06/1989)

documentation and coordination of care all on the same day. Time is the basis of this E & M CPT code. This was a telehealth visit due to a recent local flare of the pandemic.

ROS

Constitutional: Constitutional: no fever or night sweats.

ENMT: Nose: no frequent nosebleeds. Mouth/Throat: no bleeding gums.

Cardiovascular: Cardiovascular: no palpitations.

Respiratory: Respiratory: no coughing up blood.

Genitourinary: Genitourinary: no incontinence.

Musculoskeletal: Musculoskeletal: **neck pain**.

Integumentary: Skin: no jaundice or rashes.

Neurologic: Neurologic: no loss of consciousness.

Hematologic/Lymphatic: Hematologic/Lymphatic no bruising or excessive bleeding.

Physical Exam

Patient is a 31-year-old female.

Chaperone: Chaperone: offered and declined.

Constitutional: General Appearance: healthy-appearing, well-nourished, and well-developed. Level of Distress: NAD.

Psychiatric: Insight: good judgement. Mental Status: normal mood and affect and active and alert. Orientation: to time, place, and person. Memory: recent memory normal and remote memory normal.

Assessment / Plan

With progression of her symptoms since last year and the severity of he January 2020 cervical spine MRI I recommended repeating it in preparation for a surgical evaluation.

1. Spinal stenosis in cervical region
M48.02: Spinal stenosis, cervical region

- MRI, CERVICAL SPINE, W/O CONTRAST

  Place of service: OFFICE
  Procedure code: 72141

  Authorization: *SELF PAY* | NOTREQUIRED | Not Required for 72141
- XR, CERVICAL SPINE

  Views (X-RAY, CERVICAL SPINE): AP, Lateral, Flexion & Extension

  Place of service: OFFICE
  Procedure code: 72052, 72040, 72050

  Authorization: *SELF PAY* | NOTREQUIRED | Not Required for 72040, 72050, 72052

Return to Office

Patient will return to the office as needed.

Encounter Sign-Off

Encounter signed-off by John L. Mansell, MD, 09/24/2021.

Encounter performed and documented by John L. Mansell, MD
Encounter reviewed & signed by John L. Mansell, MD on 09/24/2021 at 05:47 AM

PULLIAM, Viktoriya (id #6945, dob: 12/06/1989)

Encounter Date: 08/12/2021

Patient

Name	PULLIAM, VIKTORIYA (31yo, F) ID# 6945	**Appt. Date/Time**	08/12/2021 03:45PM
DOB	12/06/1989	**Service Dept.**	WPI-Gillette
Provider	JOHN L. MANSELL, MD		
Insurance	Med Primary: *SELF PAY* Prescription: CVS|CAREMARK - Member is eligible. details		

Chief Complaint

neck pain with left arm tingling

Patient's Care Team

Referring Provider: JUSTIN MERRYMAN DC: 201 W LAKEWAY RD STE 211, GILLETTE, WY 82718, Ph (307) 217-2323, Fax (307) 228-2184 NPI: 1790227866
Primary Care Provider: AMY HAWK APRN: 501 S BURMA AVE, GILLETTE, WY 82716, Ph (307) 688-3535, Fax (307) 688-7916

Patient's Pharmacies

WALGREENS DRUG STORE #07928 (ERX): 2000 S DOUGLAS HWY, GILLETTE, WY 82718, Ph (307) 682-4517, Fax (307) 682-4563

Vitals

Ht:	5 ft 6 in Stated 08/12/2021 03:57 pm	**Wt:**	157 lbs Stated 08/12/2021 03:58 pm	**BMI:**	25.3 08/12/2021 03:58 pm
HR:	77 08/12/2021 03:58 pm	**BP:**	127/83 sitting L arm 08/12/2021 03:58 pm	**T:**	97.8 F° temporal artery 08/12/2021 03:58 pm
O2Sat:	96% Room Air at Rest 08/12/2021 03:58 pm	**Pain Scale:**	0 08/12/2021 03:58 pm		

Allergies

Reviewed Allergies

PENICILLINS

Medications

PULLIAM, Viktoriya (id #6945, dob: 12/06/1989)

Reviewed Medications

acyclovir 5 % topical ointment APPLY TOPICALLY TO THE AFFECTED AREA 6 TIMES DAILY FOR 7 DAYS	07/23/21	filled
escitalopram 20 mg tablet TAKE 1 TABLET BY MOUTH EVERY DAY	07/29/21	filled
gabapentin 100 mg capsule TAKE 1 CAPSULE BY MOUTH THREE TIMES DAILY	07/23/21	filled
methylPREDNISolone 4 mg tablets in a dose pack FOLLOW PACKAGE DIRECTIONS	07/23/21	filled
OXcarbazepine 300 mg tablet 1-2 po q hs	08/12/21	prescribed
prednisoLONE acetate 1 % eye drops,suspension SHAKE LIQUID AND INSTILL 1 DROP IN BOTH EYES THREE TIMES DAILY	07/23/21	filled
valACYclovir 1 gram tablet TAKE 1 TABLET BY MOUTH THREE TIMES DAILY X 7 DAYS FOR OUTBREAKS/PAINFUL LESION	07/23/21	filled

Problems

Reviewed Problems
No known problems

Family History

Reviewed Family History

Unspecified Relation	- Family history of alcoholism - Grandfather
	- Diabetes mellitus - Grandmother
	- Family history of cancer - Grandmother- ovarian , brain ca
Brother	- Family history of substance abuse - Illegal Drug Abuse
Father	- Heart disease
	- Hypertensive disorder

Social History

Reviewed Social History
Other
Live alone or with others?: with others
Education and Occupation
Are you currently employed?: Yes
Substance Use
Do you or have you ever smoked tobacco?: Former smoker
Do you or have you ever used smokeless tobacco?: Never used smokeless tobacco
How much tobacco do you chew?: none
What was the date of your most recent tobacco screening?: 08/12/2021
Do you use any illicit or recreational drugs?: No
What is your level of caffeine consumption?: Moderate
Public Health and Travel
Have you been to an area known to be high risk for COVID-19?: No
Gender Identity and LGBTQ Identity
Gender identity: Choose not to disclose
Assigned sex at birth: Choose not to disclose

PULLIAM, Viktoriya (id #6945, dob: 12/06/1989)

Sexual orientation: Choose not to disclose

Surgical History

Reviewed Surgical History

GYN History

Reviewed GYN History

Obstetric History

Reviewed Obstetric History

Past Medical History

Reviewed Past Medical History
Anxiety Disorder: **Y**
Head Trauma/Injury: **Y**
Headaches: **Y**

Screening

Name	Score	Notes
PHQ-2/PHQ-9	8 (for the PHQ-9), Finding: Positive	
GAD-7	2	

HPI

This is a pleasant 31-year-old lady with neck pain over her posterior neck accompanied by tingling in her left arm diffusely. The tingling in the left arm is not accompanied by pain but does occur with changes in neck position. The tingling does not follow any particular peripheral nerve or dermatomal pattern. It is only in the left arm and not the right. She denies any changes in strength in the left arm.
In the past she has tried gabapentin for this but it caused severe nightmares. We recently performed a cervical epidural steroid injection with no relief or change in either pain in the neck or tingling in the left arm.
This tingling dates back to one of her car accidents.
She has never tried a sodium channel blocker to see if this would manage the tingling.
We do not have a copy of her Oregon cervical spine MRI but asked her to sign a release for one.

The results of their depression and anxiety screening tests were normal and no action is needed at this time for her mild depression.

I spent 20 minutes with this patient which consisted of chart review, patient interview and examination, documentation and coordination of care all on the same day. Time is the basis of this E & M CPT code.

ROS

Constitutional: Constitutional: no fever or night sweats.

ENMT: Nose: no frequent nosebleeds. Mouth/Throat: no bleeding gums.

Cardiovascular: Cardiovascular: no palpitations.

Respiratory: Respiratory: no coughing up blood.

Gastrointestinal: Gastrointestinal: not vomiting blood.

Musculoskeletal: Musculoskeletal: **neck pain**.

Integumentary: Skin: no jaundice or rashes.

Neurologic: Neurologic: no seizures or loss of consciousness and **numbness**.

Psychiatric: Psych: no depression, hallucinations, or suicidal thoughts.

Hematologic/Lymphatic: Hematologic/Lymphatic no bruising or excessive bleeding.

Allergic/Immunologic: Allergy/Immunologic: no itching or hives.

Physical Exam

Patient is a 31-year-old female.

Chaperone: Chaperone: offered and declined.

Constitutional: General Appearance: healthy-appearing, well-nourished, and well-developed. Level of Distress: NAD. Ambulation: ambulating normally.

Psychiatric: Insight: good judgement. Mental Status: normal mood and affect and active and alert. Orientation:

PULLIAM, Viktoriya (id #6945, dob: 12/06/1989)

to time, place, and person. Memory: recent memory normal and remote memory normal.

Head: Head: normocephalic and atraumatic; **non-tender occipital nerves**.

Eyes: Lids and Conjunctivae: non-injected and no discharge. Pupils: PERRLA. EOM: EOMI. Sclerae: non-icteric.

ENMT: Nose: no lesions on external nose or nasal discharge. Lips, Teeth, and Gums: no bleeding gums.

Lungs: Respiratory effort: no dyspnea.

Neurologic: Cranial Nerves: grossly intact. Sensation: grossly intact (**to light touch of the upper extremities**). Hoffmans Cervical Spine Reflex Left hand Hoffman's normal (-) and Right hand Hoffman's normal (-). ATHENA Cervical Spine Strength **Symmetric and normal strength deltoids, triceps, biceps, wrist flexion and extension and grip**.

Skin: Inspection and palpation: good turgor and no jaundice.

Back: Thoracolumbar Appearance: **normal posture with negative Spurling's in neutral and tilted postures, non-tender cervical spinous processes, negative cervical facet loading signs.**.

Assessment / Plan

Her neck pain got no better after her cervical epidural steroid injection and her exam is not very enlightening today.

With her description of numbness and tingling over her whole arm, not just in a dermatome or peripheral nerve pattern, one would be more suspicious of a brachial plexus injury.

1. Chronic neck pain
M54.2: Cervicalgia

2. Paresthesia of upper limb
R20.2: Paresthesia of skin
- oxcarbazepine 300 mg tablet - 1-2 po q hs Qty: 60 tablet(s) Refills: 0 Pharmacy: WALGREENS DRUG STORE #07928

3. Depression screening -
The results of their depression and anxiety screening tests were normal and no action is needed at this time for only mild depression.
Z13.31: Encounter for screening for depression

Return to Office

- John L. Mansell, MD for Follow Up at WPI-Gillette on 09/23/2021 at 01:00 PM

Encounter Sign-Off

Encounter signed-off by John L. Mansell, MD, 08/12/2021.

Encounter performed and documented by John L. Mansell, MD
Encounter reviewed & signed by John L. Mansell, MD on 08/12/2021 at 05:19 PM

PULLIAM, Viktoriya (id #6945, dob: 12/06/1989)

Encounter Date: 06/24/2021

Patient

Name	PULLIAM, VIKTORIYA (31yo, F) ID# 6945	**Appt. Date/Time**	06/24/2021 03:45PM
DOB	12/06/1989	**Service Dept.**	WPI-Gillette
Provider	JOHN L. MANSELL, MD		
Insurance	Med Primary: *SELF PAY* Prescription: CVS|CAREMARK - Member is eligible. details		

Chief Complaint

neck and shoulder pain

Patient's Care Team

Referring Provider: JUSTIN MERRYMAN DC: 201 W LAKEWAY RD STE 211, GILLETTE, WY 82718, Ph (307) 217-2323, Fax (307) 228-2184 NPI: 1790227866
Primary Care Provider: AMY HAWK APRN: 501 S BURMA AVE, GILLETTE, WY 82716, Ph (307) 688-3535, Fax (307) 688-7916

Patient's Pharmacies

WALGREENS DRUG STORE #07928 (ERX): 2000 S DOUGLAS HWY, GILLETTE, WY 82718, Ph (307) 682-4517, Fax (307) 682-4563

Vitals

10/29/2021 02:16 pm

Ht: 5 ft 6 in

Allergies

Allergies not reviewed (last reviewed 04/28/2021)

PENICILLINS

Medications

Reviewed Medications

acyclovir 5 % topical ointment APPLY TOPICALLY TO THE AFFECTED AREA 6 TIMES DAILY FOR 7 DAYS	07/23/21	filled
cabergoline 0.5 mg tablet TAKE 1 TABLET BY MOUTH EVERY DAY	08/18/21	filled
escitalopram 20 mg tablet TAKE 1 TABLET BY MOUTH EVERY DAY	10/11/21	filled
methylPREDNISolone 4 mg tablets in a dose pack FOLLOW PACKAGE DIRECTIONS	07/23/21	filled
OXcarbazepine 300 mg tablet TAKE 1 TO 2 TABLETS BY MOUTH AT BEDTIME	08/12/21	filled
prednisoLONE acetate 1 % eye drops,suspension SHAKE LIQUID AND INSTILL 1 DROP IN BOTH EYES THREE TIMES DAILY	07/23/21	filled
valACYclovir 1 gram tablet TAKE 1 TABLET BY MOUTH THREE TIMES DAILY X 7 DAYS FOR OUTBREAKS/PAINFUL LESION	07/23/21	filled

Problems

PULLIAM, Viktoriya (id #6945, dob: 12/06/1989)

Reviewed Problems
No known problems

Family History

Reviewed Family History

Unspecified Relation	- Family history of alcoholism - Grandfather
	- Diabetes mellitus - Grandmother
	- Family history of cancer - Grandmother- ovarian , brain ca
Brother	- Family history of substance abuse - Illegal Drug Abuse
Father	- Heart disease
	- Hypertensive disorder

Social History

Reviewed Social History
Other
Live alone or with others?: with others
Education and Occupation
Are you currently employed?: Yes
Substance Use
Do you or have you ever smoked tobacco?: Former smoker
Do you or have you ever used smokeless tobacco?: Never used smokeless tobacco
How much tobacco do you chew?: none
What was the date of your most recent tobacco screening?: 09/23/2021
Do you use any illicit or recreational drugs?: No
What is your level of caffeine consumption?: Moderate
Public Health and Travel
Have you been to an area known to be high risk for COVID-19?: No
Gender Identity and LGBTQ Identity
Gender identity: Choose not to disclose
Assigned sex at birth: Choose not to disclose
Sexual orientation: Choose not to disclose

Surgical History

Surgical History not reviewed (last reviewed 04/28/2021)

GYN History

GYN History not reviewed (last reviewed 04/28/2021)

Obstetric History

Obstetric History not reviewed (last reviewed 04/28/2021)

Past Medical History

Past Medical History not reviewed (last reviewed 04/28/2021)
Anxiety Disorder: **Y**
Head Trauma/Injury: **Y**
Headaches: **Y**

Screening

None recorded.

HPI

This is a pleasant 31 year old lady with a history of bilateral lower neck and shoulder pain referred by Dr. Merryman for a trial of a cervical epidural steroid injection.

Risks of this were reviewed with them including bleeding, infection, nerve damage, spinal cord damage, paraplegia, quadriplegia, permanent incontinence and death. They are taking no anticoagulant medications and have a review of systems negative for coagulopathic symptoms, no easy bruising, gingival bleeding or epistaxis. They are afebrile with no infectious disease symptoms.

Informed consent was obtained.

ROS

Constitutional: Constitutional: no fever or night sweats.

ENMT: Nose: no frequent nosebleeds. Mouth/Throat: no bleeding gums.

PULLIAM, Viktoriya (id #6945, dob: 12/06/1989)

Hematologic/Lymphatic: Hematologic/Lymphatic no bruising or excessive bleeding.

Physical Exam

None recorded.

Procedure Documentation

Cervical Epidural Steroid Injection:

Risks of this were reviewed with her including bleeding, infection, nerve damage, spinal cord damage, paraplegia, quadriplegia, permanent incontinence and death. She is taking no blood thinner medications and has a review of systems negative for coagulopathic symptoms. She is afebrile with no recent infectious disease symptoms. Informed consent was obtained.

In a prone position on the fluoroscopy table after a timeout was observed her upper back and posterior neck or prepped widely with Betadine and draped in the usual sterile fashion. Using a C-arm fluoroscopic unit the C7 T-1 interlaminar space was visualized and through topical cold spray and lidocaine infiltration a 22 gauge Tuohy needle was walked off inferior aspect of the left C7 lamina and into the epidural space with loss of resistance technique using 2 mL of Omnipaque 240 contrast which yielded an immediate epidurogram. Following another negative aspirate for milliliters comprised of 3 mL or 30 mg of dexamethasone and 1 mL of 0.25% bupivacaine (both preservative free) was injected displacing the previously noted dye pattern. The needle was withdrawn intact. A Band-Aid was placed on the site.

A list of side effects, complications and their symptoms were reviewed with her and she was instructed to contact us should any of these give her concern. The delayed onset of steroid effect with transient exacerbation of symptoms was explained to them as well and they were discharged without incident.

Assessment / Plan

The procedure went smoothly and she tolerated it well.

1. Cervical radiculitis
M54.12: Radiculopathy, cervical region

Return to Office

Patient will return to the office as needed.

Encounter Sign-Off

Encounter signed-off by John L. Mansell, MD, 10/30/2021.

Encounter performed and documented by John L. Mansell, MD
Encounter reviewed & signed by John L. Mansell, MD on 10/30/2021 at 08:19 AM

PULLIAM, Viktoriya (id #6945, dob: 12/06/1989)

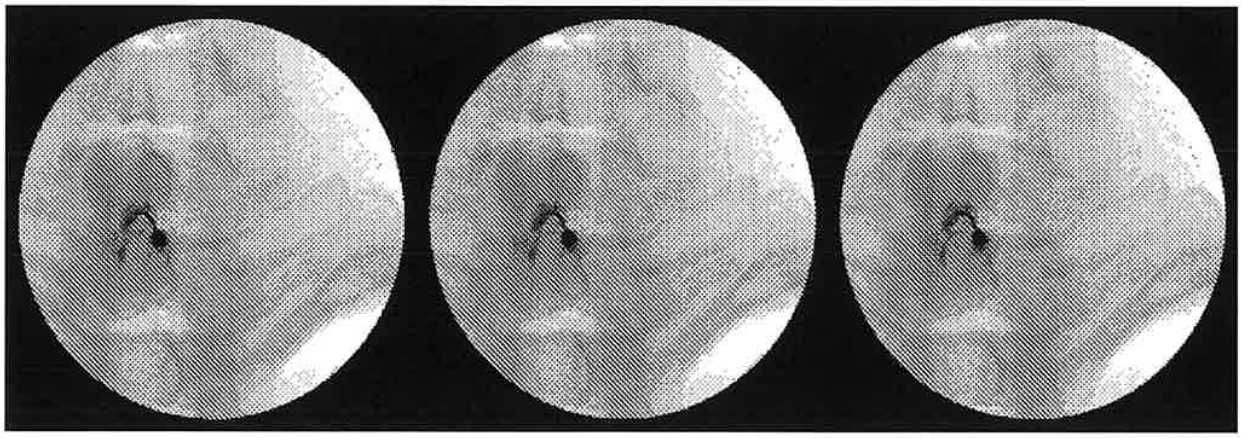

PULLIAM, Viktoriya (id #6945, dob: 12/06/1989)

Encounter Date: 04/28/2021

Patient

Name	PULLIAM, VIKTORIYA (31yo, F) ID# 6945	**Appt. Date/Time**	04/28/2021 01:30PM
DOB	12/06/1989	**Service Dept.**	WPI-Gillette
Provider	JOHN L. MANSELL, MD		
Insurance	Med Primary: *SELF PAY* Prescription: CVS|CAREMARK - Member is eligible. details		

Chief Complaint

low back pain

Patient's Pharmacies

WALGREENS DRUG STORE #07928 (ERX): 2000 S DOUGLAS HWY, GILLETTE, WY 82718, Ph (307) 682-4517, Fax (307) 682-4563

Vitals

Ht:	5 ft 6 in Stated 04/28/2021 01:37 pm	**Wt:**	157 lbs Stated 04/28/2021 01:37 pm	**BMI:**	25.3 04/28/2021 01:37 pm
HR:	81 04/28/2021 01:37 pm	**BP:**	117/75 sitting L arm 04/28/2021 01:37 pm	**T:**	97.7 F° temporal artery 04/28/2021 01:38 pm
O2Sat:	97% Room Air at Rest 04/28/2021 01:38 pm	**Pain Scale:**	4 04/28/2021 01:38 pm		

Allergies

Reviewed Allergies

PENICILLINS

Medications

Reviewed Medications

escitalopram 20 mg tablet TAKE 1 TABLET BY MOUTH EVERY DAY	04/21/21	filled
HYDROcodone 5 mg-acetaminophen 325 mg tablet 1 po up to BID prn pain	04/28/21	prescribed
predniSONE 10 mg tablet 1 po q day for 5 days	04/28/21	prescribed

Problems

Reviewed Problems
No known problems

Family History

Reviewed Family History

PULLIAM, Viktoriya (id #6945, dob: 12/06/1989)

Unspecified Relation	- Family history of alcoholism - Grandfather
	- Diabetes mellitus - Grandmother
	- Family history of cancer - Grandmother- ovarian , brain ca
Brother	- Family history of substance abuse - Illegal Drug Abuse
Father	- Heart disease
	- Hypertensive disorder

Social History

Reviewed Social History
Education and Occupation
Are you currently employed?: Yes
Substance Use
Do you or have you ever smoked tobacco?: Former smoker
Do you or have you ever used smokeless tobacco?: Never used smokeless tobacco
How much tobacco do you chew?: none
What was the date of your most recent tobacco screening?: 04/28/2021
Do you use any illicit or recreational drugs?: No
What is your level of caffeine consumption?: Moderate
Public Health and Travel
Have you been to an area known to be high risk for COVID-19?: No
Gender Identity and LGBTQ Identity
Gender identity: Choose not to disclose
Assigned sex at birth: Choose not to disclose
Sexual orientation: Choose not to disclose

Surgical History

Reviewed Surgical History

GYN History

Reviewed GYN History

Obstetric History

Reviewed Obstetric History

Past Medical History

Reviewed Past Medical History
Anxiety Disorder: **Y**
Head Trauma/Injury: **Y**
Headaches: **Y**

Screening

None recorded.

HPI

This is a pleasant 31 year old lady with a history of bilateral lower back pain referred by Dr. Merryman for bilateral L3 to S1 rhizotomies.

Risks of this were reviewed with them including bleeding, infection, nerve damage, spinal cord damage, paraplegia, quadriplegia, permanent incontinence and death. They are taking no anticoagulant medications and have a review of systems negative for coagulopathic symptoms, no easy bruising, gingival bleeding or epistaxis. They are afebrile with no infectious disease symptoms.

Informed consent was obtained.

ROS

Constitutional: Constitutional: no fever or night sweats.

ENMT: Nose: no frequent nosebleeds. Mouth/Throat: no bleeding gums.

Hematologic/Lymphatic: Hematologic/Lymphatic no bruising or excessive bleeding.

Physical Exam

None recorded.

PULLIAM, Viktoriya (id #6945, dob: 12/06/1989)

Procedure Documentation

Lumbar Radiofrequency Ablations of Medial Branch Nerves:
Bilateral L3 to S1 Radiofrequency Ablations of Medial Branch Nerves

Risks of this were reviewed with her including bleeding, infection, nerve damage, spinal cord damage, paraplegia, quadriplegia, permanent incontinence and death. She is taking no blood thinner medications and has a review of systems negative for coagulopathic symptoms. She is afebrile with no recent infectious disease symptoms. Informed consent was obtained.
In a prone position on the fluoroscopy table after a timeout was observed her back was prepped widely with Betadine and draped in the usual sterile fashion. Using a C-arm telescopic unit and an AP view the transverse processes bilaterally at L3, L4 and L5 as well as the sacral alae were visualized and through topical cold spray and an acupuncture needle insertion technique 18gauge radiofrequency needles were placed on the superior aspect of the medial third of each of these locations at these levels bilaterally and incremental moves were made until successful stimulation was achieved at 50 Hz at less than .5 V with negative motor stimulation at 2 Hz at triple the sensory threshold. After this was accomplished 2.5 mL of 0.75% bupivacaine with 4 mg/mL of Depo-Medrol admixed was injected to each needle and we waited five minutes before performing ablations at 80°C for 75 seconds. Two 120° clockwise turns were performed within ablation after each turn for a total of three ablations at each level. All needles were withdrawn intact. Band-Aids were placed on the sites.

She was returned to the postprocedure observation area where she appeared to tolerate the procedure well. A list of side effects, complications and their symptoms were reviewed with her and she was instructed to contact us should any of these give them concern. She tolerated the procedure well and was discharged without incident.

He was returned to the postprocedure observation area where he appeared to tolerate the procedure well. A list of side effects, complications and their symptoms were reviewed with him and he was instructed to contact us should any of these give him concern. The delayed onset of steroid effect with transit exacerbation of symptoms was explained to him as well and he was discharged without incident.

Assessment / Plan

The procedure went smoothly and she tolerated it well.

1. Lumbosacral spondylosis without myelopathy
M47.817: Spondylosis without myelopathy or radiculopathy, lumbosacral region

- hydrocodone 5 mg-acetaminophen 325 mg tablet - 1 po up to BID prn pain Qty: 14 tablet(s) Refills: 0 Pharmacy: WALGREENS DRUG STORE #07928
- prednisone 10 mg tablet - 1 po q day for 5 days Qty: 5 tablet(s) Refills: 0 Pharmacy: WALGREENS DRUG STORE #07928

Return to Office

None recorded.

Encounter Sign-Off

Encounter signed-off by John L. Mansell, MD, 04/28/2021.

Encounter performed and documented by John L. Mansell, MD
Encounter reviewed & signed by John L. Mansell, MD on 04/28/2021 at 03:11 PM

PULLIAM, Viktoriya (id #6945, dob: 12/06/1989)

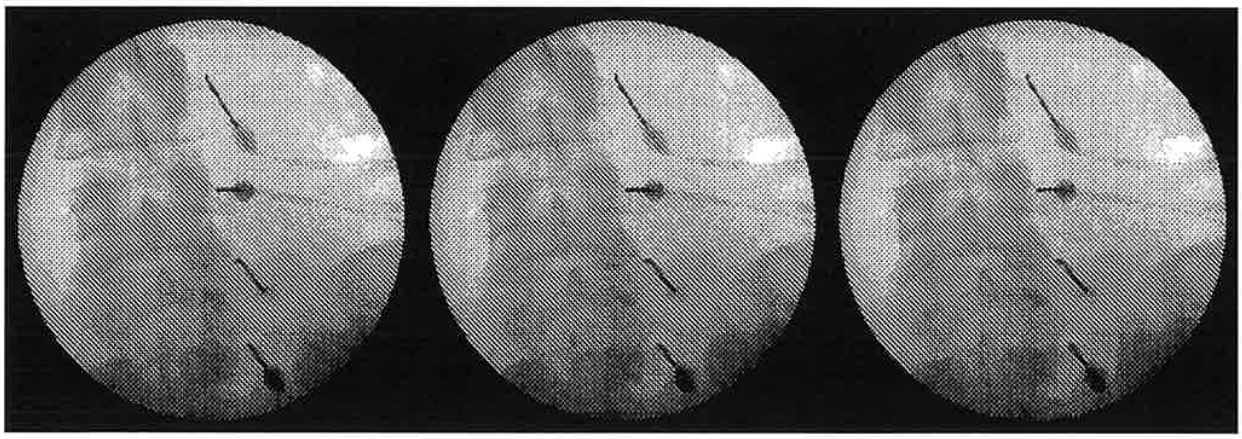

PULLIAM, Viktoriya (id #6945, dob: 12/06/1989)

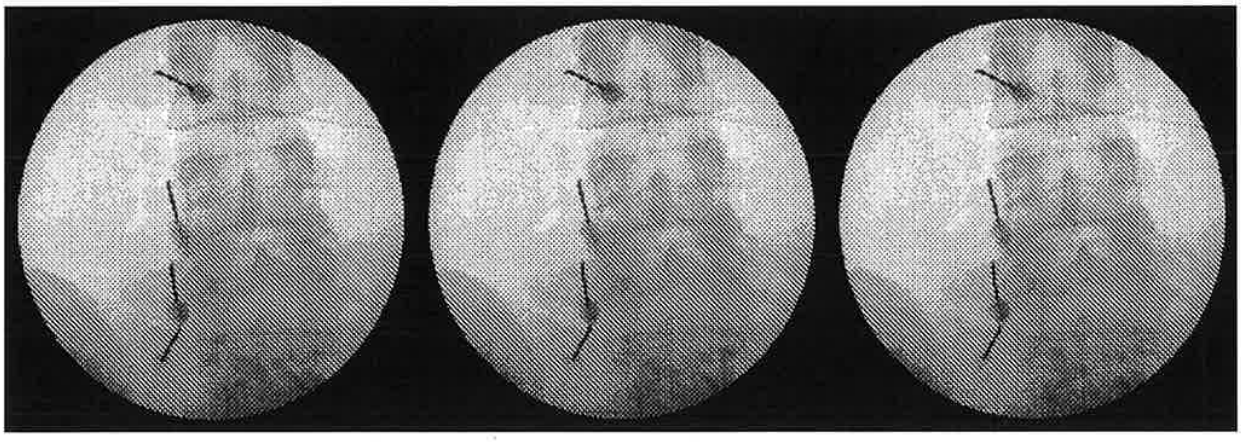

PULLIAM, Viktoriya (id #6945, dob: 12/06/1989)

Encounter Date: 04/14/2021

Patient

Name	PULLIAM, VIKTORIYA (31yo, F) ID# 6945	**Appt. Date/Time**	04/14/2021 03:30PM
DOB	12/06/1989	**Service Dept.**	WPI-Gillette
Provider	JOHN L. MANSELL, MD		
Insurance	Med Primary: *SELF PAY* Prescription: CVS|CAREMARK - Member is eligible. details		

Chief Complaint

Scheduled Procedure

low back pain

Vitals

Ht:	5 ft 6 in Stated 04/14/2021 03:48 pm	**Wt:**	157 lbs Stated 04/14/2021 03:49 pm	**BMI:**	25.3 04/14/2021 03:49 pm
HR:	67 04/14/2021 03:49 pm	**BP:**	105/64 sitting L arm 04/14/2021 03:49 pm	**T:**	97.5 F° temporal artery 04/14/2021 03:49 pm
O2Sat:	96% Room Air at Rest 04/14/2021 03:49 pm	**Pain Scale:**	3 04/14/2021 03:49 pm		

Allergies

Reviewed Allergies

PENICILLINS

Medications

Reviewed Medications

escitalopram 20 mg tablet 03/12/21 filled
TAKE 1 TABLET BY MOUTH EVERY DAY

Problems

Reviewed Problems
No known problems

Family History

Reviewed Family History

Unspecified Relation	- Family history of alcoholism - Grandfather
	- Diabetes mellitus - Grandmother
	- Family history of cancer - Grandmother- ovarian , brain ca
Brother	- Family history of substance abuse - Illegal Drug Abuse
Father	- Heart disease
	- Hypertensive disorder

Social History

Reviewed Social History
Education and Occupation
Are you currently employed?: Yes

PULLIAM, Viktoriya (id #6945, dob: 12/06/1989)

Substance Use
Do you or have you ever smoked tobacco?: Former smoker
Do you or have you ever used smokeless tobacco?: Never used smokeless tobacco
How much tobacco do you chew?: none
What was the date of your most recent tobacco screening?: 04/14/2021
Do you use any illicit or recreational drugs?: No
What is your level of caffeine consumption?: Moderate
Public Health and Travel
Have you been to an area known to be high risk for COVID-19?: No
Gender Identity and LGBTQ Identity
Gender identity: Choose not to disclose
Assigned sex at birth: Choose not to disclose
Sexual orientation: Choose not to disclose

Surgical History

Reviewed Surgical History

GYN History

Reviewed GYN History

Obstetric History

Reviewed Obstetric History

Past Medical History

Reviewed Past Medical History
Anxiety Disorder: **Y**
Head Trauma/Injury: **Y**
Headaches: **Y**

Screening

None recorded.

HPI

This is a pleasant 31 year old lady with a history of bilateral lower back pain referred by Dr. Merryman for a trial of bilateral L3 to S1 lumbar medial branch blocks.

Risks of this were reviewed with them including bleeding, infection, nerve damage, spinal cord damage, paraplegia, quadriplegia, permanent incontinence and death. They are taking no anticoagulant medications and have a review of systems negative for coagulopathic symptoms, no easy bruising, gingival bleeding or epistaxis. They are afebrile with no infectious disease symptoms.

Informed consent was obtained.

ROS

Constitutional: Constitutional: no fever or night sweats.

ENMT: Nose: no frequent nosebleeds. Mouth/Throat: no bleeding gums.

Hematologic/Lymphatic: Hematologic/Lymphatic no bruising or excessive bleeding.

Physical Exam

None recorded.

Procedure Documentation

Lumbar Medial Branch Blocks:
Bilateral L3 to S1 Lumbar Medial Branch Blocks

Risks of lumbar medial branch blocks were reviewed with the patient including bleeding, infection, nerve damage, spinal cord damage, paraplegic, quadriplegic, permanent incontinence and death. The patient is taking no anticoagulant medications and has a review of systems negative for coagulopathic symptoms including bleeding, infection, nerve damage, spinal cord damage, paraplegic, quadriplegic, permanent incontinence and death. They are afebrile with no recent infectious disease symptoms. Informed consent was obtained.

in a prone position on the fluoroscopy table after a timeout was performed the transverse processes from L3 to S1 bilaterally were visualized fluoroscopically and after prepping and draping in the usual sterile fashion through topical cold spray and an acupuncture needle insertion technique a 25gauge 3.5" needle was placed down to the superior aspect of the medial third of each of these transverse processes bilaterally at these levels. Following a negative aspirate on each needle 1 mL of Omnipaque 200 contrast

PULLIAM, Viktoriya (id #6945, dob: 12/06/1989)

was injected through each needle yielding a supra-cortical pattern of spread. Following another negative aspirate 1 mL of 0.75% bupivacaine was injected through each needle displacing the previously noted dye patterns. The needles were withdrawn intact. Band-Aids were placed on the sites.

The patient was returned to the post-procedure observation area where after one hour they reported their pain dropped from an "3" to a "1" or "75%" better. She was sent home with a three-day pain diary as well.

A list of side effects, complications and their symptoms were reviewed with them and they were instructed to contact us should any of these give them concern. The transient nature of diagnostic blocks was explained to them as well and they were discharged without incident. They tolerated the procedure well.

Assessment / Plan

The procedure went smoothly and she tolerated it well.

1. Possible pregnancy
Z32.00: Encounter for pregnancy test, result unknown
- PREGNANCY TEST, URINE - Specimen source: Urine

2. Lumbosacral spondylosis without myelopathy
M47.817: Spondylosis without myelopathy or radiculopathy, lumbosacral region

Return to Office

None recorded.

Encounter Sign-Off

Encounter signed-off by John L. Mansell, MD, 04/14/2021.

Encounter performed and documented by John L. Mansell, MD
Encounter reviewed & signed by John L. Mansell, MD on 04/14/2021 at 05:21 PM

PULLIAM, Viktoriya (id #6945, dob: 12/06/1989)

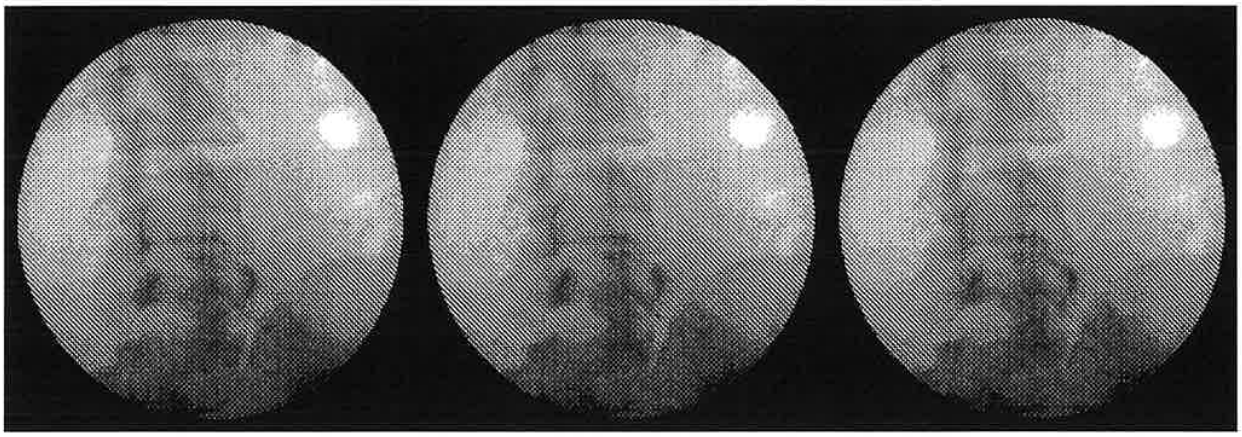

PULLIAM, Viktoriya (id #6945, dob: 12/06/1989)

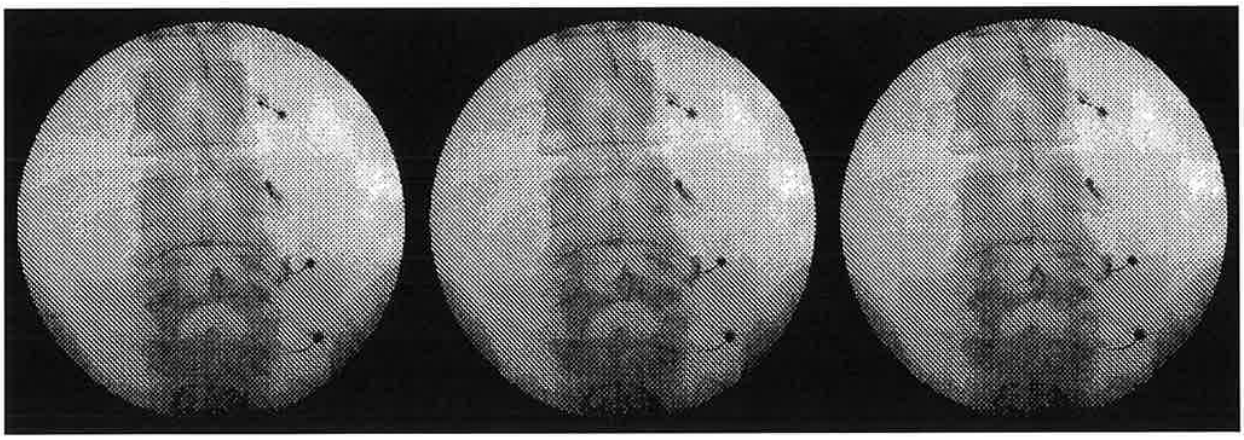

PULLIAM, Viktoriya (id #6945, dob: 12/06/1989)

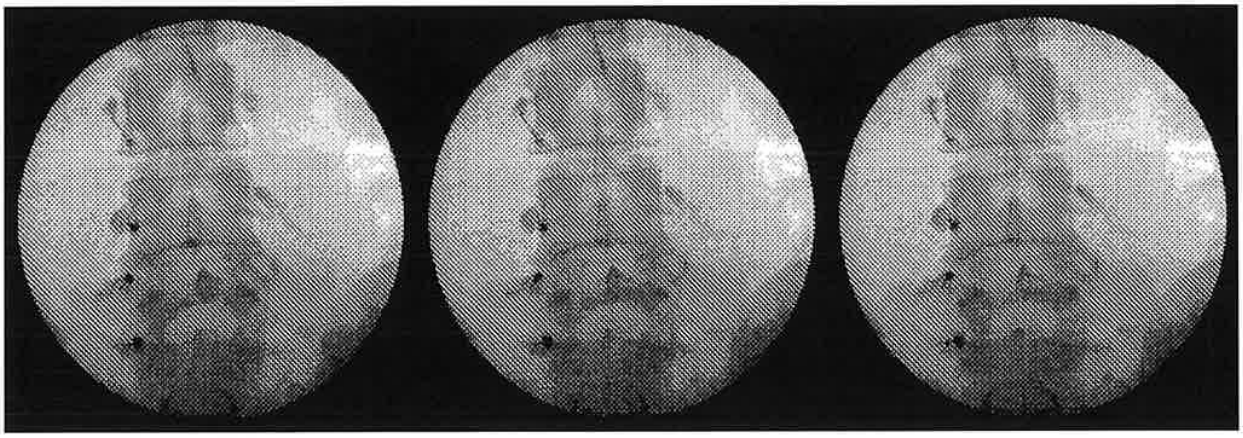

PULLIAM, Viktoriya (id #6945, dob: 12/06/1989)

Encounter Date: 04/12/2021

Patient

Name	PULLIAM, VIKTORIYA (31yo, F) ID# 6945	**Appt. Date/Time**	04/12/2021 09:30AM
DOB	12/06/1989	**Service Dept.**	WPI-Gillette
Provider	JOHN L. MANSELL, MD		
Insurance	Med Primary: *SELF PAY* Prescription: CVS|CAREMARK - Member is eligible. details		

Chief Complaint

low back pain

Vitals

04/12/2021 09:49 am

Ht: 5 ft 6 in Stated **Wt:** 157 lbs Stated **BMI:** 25.3

HR: 59

Allergies

Reviewed Allergies

PENICILLINS

Medications

Reviewed Medications

escitalopram 20 mg tablet 03/12/21 filled
TAKE 1 TABLET BY MOUTH EVERY DAY

Problems

Reviewed Problems
No known problems

Family History

Reviewed Family History

Unspecified Relation	- Family history of alcoholism - Grandfather
	- Diabetes mellitus - Grandmother
	- Family history of cancer - Grandmother- ovarian , brain ca
Brother	- Family history of substance abuse - Illegal Drug Abuse
Father	- Heart disease
	- Hypertensive disorder

Social History

Reviewed Social History
Education and Occupation
Are you currently employed?: Yes
Substance Use
Do you or have you ever smoked tobacco?: Former smoker
Do you or have you ever used smokeless tobacco?: Never used smokeless tobacco
How much tobacco do you chew?: none
What was the date of your most recent tobacco screening?: 04/14/2021
Do you use any illicit or recreational drugs?: No
What is your level of caffeine consumption?: Moderate
Public Health and Travel
Have you been to an area known to be high risk for COVID-19?: No

PULLIAM, Viktoriya (id #6945, dob: 12/06/1989)

Gender Identity and LGBTQ Identity
Gender identity: Choose not to disclose
Assigned sex at birth: Choose not to disclose
Sexual orientation: Choose not to disclose

Surgical History

Reviewed Surgical History

GYN History

Reviewed GYN History

Obstetric History

Reviewed Obstetric History

Past Medical History

Reviewed Past Medical History
Anxiety Disorder: **Y**
Head Trauma/Injury: **Y**
Headaches: **Y**

Screening

Name	Score	Notes
Opioid Risk	4	

HPI

This is a pleasant 31-year-old lady with a history of back pain that dates back to two motor vehicle accidents in November 2019 and February 2020. In the first accident she was struck from the driver side while restrained and in February 2020 she was struck on the passenger side. Since these accidents she has felt that her back pain has progressively gotten worse.

She describes a 3 inch high area of pain that spans her back with about 70% on the left side and 30% on the right which may also refer down the left lateral thigh in a 1 inch wide stripe to her knee.

Overall she apportions the pain is 90% in her back and 10% in her left leg.

She also reports pain over the lower thoracic spine that will also go down into her back on a daily basis with more severe episodes happening on average twice a week.

She describes the pain is achy with electric sensation as well as pressure, throbbing, horizontal and vertical pulling and a sense of tightness in her back.

In the last month the pain is been as severe as 8/10 and as low as 0/10.

When she gets up in the morning the pain tends to be worse for about an hour and by noon it is typically more severe. It awakens her every night.

Exacerbating factors include standing more than 5 to 10 minutes, lying in any static position more than 30 minutes, rolling over in her sleep which will awaken her with pain, stairs, straightening up at the waist which is more painful than bending forward, lifting, driving or sitting more than 10 minutes and light housework which requires frequent breaks.

Mitigating factors include lying down on her sides, leaning on other objects to take the weight off of her back or topical heat.

Associated symptoms include tingling in her legs the long drives, muscle spasms causing hip flexion as well as clicking and fine crepitance in her back. She denies any weakness or unintentional weight loss or changes in bladder or rectal control. She does say that the last year she has gained about 25 pounds.

Her most recent Pap smear was this year. She underwent an ectopic surgery in 2019 but does not feel this affected her back pain. She has taken Advil in this is helped a little bit.

Her opioid risk tool score is for or medium for a family history of alcohol and illegal drug abuse and her youth. Her urine drug screen is unremarkable.

I spent 45 minutes with this patient which consisted of chart review, patient interview and examination, documentation and coordination of care all on the same day. Time is the basis of this E & M CPT code.

ROS

Constitutional: Constitutional: no fever or night sweats.

Eyes: Eyes: **vision change**.

PULLIAM, Viktoriya (id #6945, dob: 12/06/1989)

ENMT: Nose: no frequent nosebleeds. Mouth/Throat: no bleeding gums.

Cardiovascular: Cardiovascular: no palpitations.

Gastrointestinal: Gastrointestinal: **nausea**, **vomiting**, and **constipation**.

Genitourinary: Genitourinary: no incontinence or hematuria.

Musculoskeletal: Musculoskeletal: **back pain**.

Integumentary: Skin: no jaundice or rashes.

Neurologic: Neurologic: no seizures or loss of consciousness and **dizziness** and **frequent or severe headaches**.

Psychiatric: Psych: no hallucinations and **suicidal thoughts**.

Hematologic/Lymphatic: Hematologic/Lymphatic no bruising or excessive bleeding.

Allergic/Immunologic: Allergy/Immunologic: no itching or hives.

Physical Exam

Patient is a 31-year-old female.

Chaperone: Chaperone: offered and declined.

Constitutional: General Appearance: healthy-appearing, well-nourished, and well-developed. Level of Distress: NAD.

Psychiatric: Insight: good judgement. Mental Status: normal mood and affect and active and alert. Orientation: to time, place, and person. Memory: recent memory normal and remote memory normal.

Head: Head: normocephalic and atraumatic.

Eyes: Lids and Conjunctivae: non-injected and no discharge. Pupils: PERRLA. EOM: EOMI. Sclerae: non-icteric.

ENMT: Nose: no lesions on external nose or nasal discharge. Lips, Teeth, and Gums: no bleeding gums. Oropharynx: moist mucous membranes.

Lungs: Respiratory effort: no dyspnea.

Cardiovascular: Pulses including femoral / pedal: radial right +2 and +1, radial left +2, posterior tibialis left: 1+ and right: 1+, and dorsalis pedis left: 1+.

Abdomen: Bowel Sounds: normal. Inspection and Palpation: soft, non-distended, and no tenderness.

Musculoskeletal:: Joints, Bones, and Muscles: no pain with log roll: left or right, no leg length discrepancy, and nontender to palpation: left greater trochanter and palpation: right greater trochanter. Extremities: no edema.

Neurologic: Cranial Nerves: grossly intact. Sensation: grossly intact. Coordination and Cerebellum: no tremor. Femoral Nerve Stretch: femoral nerve traction test negative (**bilaterally**). Lumbar / Lumbosacral Spine negative left straight leg raise and right straight leg raise. Hoffmans Lumbar Reflex Integrity Left foot Hoffman's normal (-) and Right foot Hoffman's normal (-). ATHENA Cervical Spine Strength **Symmetric and normal strength deltoids, triceps, biceps, wrist flexion and extension and grip, symmetric and low normal strength with hip flexion, extension, abduction and adduction, knee flexion and extension as well as dorsiflexion plantarflexion at the ankles.**.

Skin: Inspection and palpation: good turgor and no jaundice.

Back: Thoracolumbar Appearance: **normal lumbar lordosis with increased pain with lumbar extension and lumbar axial rotation, tender over the L3, L4 and L5 spinous processes but not the PSIS bilaterally, normal lumbar muscle tone with no palpable trigger points.**.

Assessment / Plan

Palpation over the L3, L4 and L5 spinous processes as well as lumbar extension were the most provocative exam maneuver and caused concordant pain. For this reason I recommended a trial of medial branch blocks at these levels.

1. Chronic pain syndrome
G89.4: Chronic pain syndrome
- DRUG SCREEN, URINE - Specimen source: Urine

2. Lumbosacral spondylosis without myelopathy

PULLIAM, Viktoriya (id #6945, dob: 12/06/1989)

M47.817: Spondylosis without myelopathy or radiculopathy, lumbosacral region

DRUG SCREEN, URINE
- Results:
  - **THC: negative**
  - **Temperature: 94 degrees**
  - **OPI: negative**
  - **AMP: negative**
  - **MET: negative**
  - **PCP: negative**
  - **BZO: negative**
  - **BAR: negative**
  - **MDMA: negative**
  - **MTD: negative**
  - **OXY: negative**
  - **TCA: negative**
  - **BUP: negative**
  - **EDDP: negative**
  - **COC: negative**

Return to Office
None recorded.

Encounter Sign-Off
Encounter signed-off by John L. Mansell, MD, 04/14/2021.

Encounter performed and documented by John L. Mansell, MD
Encounter reviewed & signed by John L. Mansell, MD on 04/14/2021 at 05:24 PM

PULLIAM, Viktoriya (id #6945, dob: 12/06/1989)

Encounter Date: 10/20/2021

Patient

Name	PULLIAM, VIKTORIYA (31yo, F) ID# 6945	**Appt. Date/Time**	10/20/2021 03:00PM
DOB	12/06/1989	**Service Dept.**	WPI-Gillette
Provider	JOHN L. MANSELL, MD		
Insurance	Med Primary: *SELF PAY* Prescription: CVS|CAREMARK - Member is eligible. details		

Chief Complaint

neck and shoulder pain

Patient's Care Team

Referring Provider: JUSTIN MERRYMAN DC: 201 W LAKEWAY RD STE 211, GILLETTE, WY 82718, Ph (307) 217-2323, Fax (307) 228-2184 NPI: 1790227866
Primary Care Provider: AMY HAWK APRN: 501 S BURMA AVE, GILLETTE, WY 82716, Ph (307) 688-3535, Fax (307) 688-7916

Patient's Pharmacies

WALGREENS DRUG STORE #07928 (ERX): 2000 S DOUGLAS HWY, GILLETTE, WY 82718, Ph (307) 682-4517, Fax (307) 682-4563

Vitals

10/20/2021 03:14 pm

Ht: 5 ft 6 in

Allergies

Reviewed Allergies

PENICILLINS

Medications

Reviewed Medications

acyclovir 5 % topical ointment APPLY TOPICALLY TO THE AFFECTED AREA 6 TIMES DAILY FOR 7 DAYS	07/23/21	filled
cabergoline 0.5 mg tablet TAKE 1 TABLET BY MOUTH EVERY DAY	08/18/21	filled
escitalopram 20 mg tablet TAKE 1 TABLET BY MOUTH EVERY DAY	10/11/21	filled
methylPREDNISolone 4 mg tablets in a dose pack FOLLOW PACKAGE DIRECTIONS	07/23/21	filled
OXcarbazepine 300 mg tablet TAKE 1 TO 2 TABLETS BY MOUTH AT BEDTIME	08/12/21	filled
prednisoLONE acetate 1 % eye drops,suspension SHAKE LIQUID AND INSTILL 1 DROP IN BOTH EYES THREE TIMES DAILY	07/23/21	filled
valACYclovir 1 gram tablet TAKE 1 TABLET BY MOUTH THREE TIMES DAILY X 7 DAYS FOR OUTBREAKS/PAINFUL LESION	07/23/21	filled

Problems

PULLIAM, Viktoriya (id #6945, dob: 12/06/1989)

Reviewed Problems
No known problems

Family History

Reviewed Family History

Unspecified Relation	- Family history of alcoholism - Grandfather
	- Diabetes mellitus - Grandmother
	- Family history of cancer - Grandmother- ovarian , brain ca
Brother	- Family history of substance abuse - Illegal Drug Abuse
Father	- Heart disease
	- Hypertensive disorder

Social History

Reviewed Social History
Other
Live alone or with others?: with others
Education and Occupation
Are you currently employed?: Yes
Substance Use
Do you or have you ever smoked tobacco?: Former smoker
Do you or have you ever used smokeless tobacco?: Never used smokeless tobacco
How much tobacco do you chew?: none
What was the date of your most recent tobacco screening?: 09/23/2021
Do you use any illicit or recreational drugs?: No
What is your level of caffeine consumption?: Moderate
Public Health and Travel
Have you been to an area known to be high risk for COVID-19?: No
Gender Identity and LGBTQ Identity
Gender identity: Choose not to disclose
Assigned sex at birth: Choose not to disclose
Sexual orientation: Choose not to disclose

Surgical History

Reviewed Surgical History

GYN History

Reviewed GYN History

Obstetric History

Reviewed Obstetric History

Past Medical History

Reviewed Past Medical History
Anxiety Disorder: **Y**
Head Trauma/Injury: **Y**
Headaches: **Y**

Screening

None recorded.

HPI

This is a record of a Zoom meeting with the patient's lawyer who wanted me to review her records from treatment prior to her arrival in Gillette. We have a consent to discuss her medical details with her attorney.

During this call he informed me that she had two automobile accidents about nine months apart and would send me details about them so I could review the details of each accident for further analysis.

We exchanged contact details.

I explained the severity of her cervical spinal stenosis and the need to have a surgical evaluation sooner rather than later.

ROS

PULLIAM, Viktoriya (id #6945, dob: 12/06/1989)

None recorded.

Physical Exam

None recorded.

Assessment / Plan

This was a meeting to discuss her case with her attorney.

1. Spinal stenosis in cervical region
M48.02: Spinal stenosis, cervical region

Return to Office

Patient will return to the office as needed.

Encounter Sign-Off

Encounter signed-off by John L. Mansell, MD, 10/20/2021.

Encounter performed and documented by John L. Mansell, MD
Encounter reviewed & signed by John L. Mansell, MD on 10/20/2021 at 8:40pm

PULLIAM, Viktoriya (id #6945, dob: 12/06/1989)

Encounter Date: 09/23/2021

Patient

Name	PULLIAM, VIKTORIYA (31yo, F) ID# 6945	**Appt. Date/Time**	09/23/2021 01:00PM
DOB	12/06/1989	**Service Dept.**	WPI-Gillette
Provider	JOHN L. MANSELL, MD		
Insurance	Med Primary: *SELF PAY* Prescription: CVS|CAREMARK - Member is eligible. details		

Chief Complaint

neck and shoulder pain with diffuse left arm tingling

Patient's Care Team

Referring Provider: JUSTIN MERRYMAN DC: 201 W LAKEWAY RD STE 211, GILLETTE, WY 82718, Ph (307) 217-2323, Fax (307) 228-2184 NPI: 1790227866
Primary Care Provider: AMY HAWK APRN: 501 S BURMA AVE, GILLETTE, WY 82716, Ph (307) 688-3535, Fax (307) 688-7916

Patient's Pharmacies

WALGREENS DRUG STORE #07928 (ERX): 2000 S DOUGLAS HWY, GILLETTE, WY 82718, Ph (307) 682-4517, Fax (307) 682-4563

Vitals

09/23/2021 01:10 pm

Ht: 5 ft 6 in **Pain Scale:** 4

Allergies

Reviewed Allergies

PENICILLINS

Medications

Reviewed Medications

acyclovir 5 % topical ointment APPLY TOPICALLY TO THE AFFECTED AREA 6 TIMES DAILY FOR 7 DAYS	07/23/21	filled
cabergoline 0.5 mg tablet TAKE 1 TABLET BY MOUTH EVERY DAY	08/18/21	filled
escitalopram 20 mg tablet TAKE 1 TABLET BY MOUTH EVERY DAY	08/22/21	filled
methylPREDNISolone 4 mg tablets in a dose pack FOLLOW PACKAGE DIRECTIONS	07/23/21	filled
OXcarbazepine 300 mg tablet TAKE 1 TO 2 TABLETS BY MOUTH AT BEDTIME	08/12/21	filled
prednisoLONE acetate 1 % eye drops,suspension SHAKE LIQUID AND INSTILL 1 DROP IN BOTH EYES THREE TIMES DAILY	07/23/21	filled
valACYclovir 1 gram tablet TAKE 1 TABLET BY MOUTH THREE TIMES DAILY X 7 DAYS FOR OUTBREAKS/PAINFUL LESION	07/23/21	filled

Problems

PULLIAM, Viktoriya (id #6945, dob: 12/06/1989)

Reviewed Problems
No known problems

Family History

Reviewed Family History

Unspecified Relation	- Family history of alcoholism - Grandfather
	- Diabetes mellitus - Grandmother
	- Family history of cancer - Grandmother- ovarian , brain ca
Brother	- Family history of substance abuse - Illegal Drug Abuse
Father	- Heart disease
	- Hypertensive disorder

Social History

Reviewed Social History
Other
Live alone or with others?: with others
Education and Occupation
Are you currently employed?: Yes
Substance Use
Do you or have you ever smoked tobacco?: Former smoker
Do you or have you ever used smokeless tobacco?: Never used smokeless tobacco
How much tobacco do you chew?: none
What was the date of your most recent tobacco screening?: 09/23/2021
Do you use any illicit or recreational drugs?: No
What is your level of caffeine consumption?: Moderate
Public Health and Travel
Have you been to an area known to be high risk for COVID-19?: No
Gender Identity and LGBTQ Identity
Gender identity: Choose not to disclose
Assigned sex at birth: Choose not to disclose
Sexual orientation: Choose not to disclose

Surgical History

Reviewed Surgical History

GYN History

Reviewed GYN History

Obstetric History

Reviewed Obstetric History

Past Medical History

Reviewed Past Medical History
Anxiety Disorder: **Y**
Head Trauma/Injury: **Y**
Headaches: **Y**

Screening

None recorded.

HPI

This is a pleasant 31 year old lady with neck and shoulder pain with left arm tingling who had undergone a previous cervical spine MRI about 18 months ago which showed severe cervical spinal stenosis at the C5-6 level with an only 5 mm AP dimension.

Since that scan her pain has gotten worse but she denies any changes in lower extremity strength or sensation or bladder or rectal control.

Because her pain has gotten worse I recommended repeating her imaging as her central canal stenosis has probably progressed as well.

We also discussed my concern that the severity of her stenosis might make her more vulnerable to more severe injury if she were to fall or be involved in a car accident. She seemed to understand this as well.

I spent 20 minutes with this patient which consisted of chart review, patient interview and examination,

PULLIAM, Viktoriya (id #6945, dob: 12/06/1989)

documentation and coordination of care all on the same day. Time is the basis of this E & M CPT code. This was a telehealth visit due to a recent local flare of the pandemic.

ROS

Constitutional: Constitutional: no fever or night sweats.

ENMT: Nose: no frequent nosebleeds. Mouth/Throat: no bleeding gums.

Cardiovascular: Cardiovascular: no palpitations.

Respiratory: Respiratory: no coughing up blood.

Genitourinary: Genitourinary: no incontinence.

Musculoskeletal: Musculoskeletal: **neck pain**.

Integumentary: Skin: no jaundice or rashes.

Neurologic: Neurologic: no loss of consciousness.

Hematologic/Lymphatic: Hematologic/Lymphatic no bruising or excessive bleeding.

Physical Exam

Patient is a 31-year-old female.

Chaperone: Chaperone: offered and declined.

Constitutional: General Appearance: healthy-appearing, well-nourished, and well-developed. Level of Distress: NAD.

Psychiatric: Insight: good judgement. Mental Status: normal mood and affect and active and alert. Orientation: to time, place, and person. Memory: recent memory normal and remote memory normal.

Assessment / Plan

With progression of her symptoms since last year and the severity of he January 2020 cervical spine MRI I recommended repeating it in preparation for a surgical evaluation.

1. Spinal stenosis in cervical region
M48.02: Spinal stenosis, cervical region

- MRI, CERVICAL SPINE, W/O CONTRAST

  Place of service: OFFICE
  Procedure code: 72141

  Authorization: *SELF PAY* | NOTREQUIRED | Not Required for 72141
- XR, CERVICAL SPINE

  Views (X-RAY, CERVICAL SPINE): AP, Lateral, Flexion & Extension

  Place of service: OFFICE
  Procedure code: 72052, 72040, 72050

  Authorization: *SELF PAY* | NOTREQUIRED | Not Required for 72040, 72050, 72052

Return to Office

Patient will return to the office as needed.

Encounter Sign-Off

Encounter signed-off by John L. Mansell, MD, 09/24/2021.

Encounter performed and documented by John L. Mansell, MD
Encounter reviewed & signed by John L. Mansell, MD on 09/24/2021 at 5:47am

PULLIAM, Viktoriya (id #6945, dob: 12/06/1989)

Encounter Date: 08/12/2021

Patient

Name	PULLIAM, VIKTORIYA (31yo, F) ID# 6945	**Appt. Date/Time**	08/12/2021 03:45PM
DOB	12/06/1989	**Service Dept.**	WPI-Gillette
Provider	JOHN L. MANSELL, MD		
Insurance	Med Primary: *SELF PAY* Prescription: CVS|CAREMARK - Member is eligible. details		

Chief Complaint

neck pain with left arm tingling

Patient's Care Team

Referring Provider: JUSTIN MERRYMAN DC: 201 W LAKEWAY RD STE 211, GILLETTE, WY 82718, Ph (307) 217-2323, Fax (307) 228-2184 NPI: 1790227866
Primary Care Provider: AMY HAWK APRN: 501 S BURMA AVE, GILLETTE, WY 82716, Ph (307) 688-3535, Fax (307) 688-7916

Patient's Pharmacies

WALGREENS DRUG STORE #07928 (ERX): 2000 S DOUGLAS HWY, GILLETTE, WY 82718, Ph (307) 682-4517, Fax (307) 682-4563

Vitals

Ht:	5 ft 6 in Stated 08/12/2021 03:57 pm	**Wt:**	157 lbs Stated 08/12/2021 03:58 pm	**BMI:**	25.3 08/12/2021 03:58 pm
HR:	77 08/12/2021 03:58 pm	**BP:**	127/83 sitting L arm 08/12/2021 03:58 pm	**T:**	97.8 F° temporal artery 08/12/2021 03:58 pm
O2Sat:	96% Room Air at Rest 08/12/2021 03:58 pm	**Pain Scale:**	0 08/12/2021 03:58 pm		

Allergies

Reviewed Allergies

PENICILLINS

Medications

PULLIAM, Viktoriya (id #6945, dob: 12/06/1989)

Reviewed Medications

acyclovir 5 % topical ointment APPLY TOPICALLY TO THE AFFECTED AREA 6 TIMES DAILY FOR 7 DAYS	07/23/21	filled
escitalopram 20 mg tablet TAKE 1 TABLET BY MOUTH EVERY DAY	07/29/21	filled
gabapentin 100 mg capsule TAKE 1 CAPSULE BY MOUTH THREE TIMES DAILY	07/23/21	filled
methylPREDNISolone 4 mg tablets in a dose pack FOLLOW PACKAGE DIRECTIONS	07/23/21	filled
OXcarbazepine 300 mg tablet 1-2 po q hs	08/12/21	prescribed
prednisoLONE acetate 1 % eye drops,suspension SHAKE LIQUID AND INSTILL 1 DROP IN BOTH EYES THREE TIMES DAILY	07/23/21	filled
valACYclovir 1 gram tablet TAKE 1 TABLET BY MOUTH THREE TIMES DAILY X 7 DAYS FOR OUTBREAKS/PAINFUL LESION	07/23/21	filled

Problems

Reviewed Problems
No known problems

Family History

Reviewed Family History

Unspecified Relation	- Family history of alcoholism - Grandfather
	- Diabetes mellitus - Grandmother
	- Family history of cancer - Grandmother- ovarian , brain ca
Brother	- Family history of substance abuse - Illegal Drug Abuse
Father	- Heart disease
	- Hypertensive disorder

Social History

Reviewed Social History
Other
Live alone or with others?: with others
Education and Occupation
Are you currently employed?: Yes
Substance Use
Do you or have you ever smoked tobacco?: Former smoker
Do you or have you ever used smokeless tobacco?: Never used smokeless tobacco
How much tobacco do you chew?: none
What was the date of your most recent tobacco screening?: 08/12/2021
Do you use any illicit or recreational drugs?: No
What is your level of caffeine consumption?: Moderate
Public Health and Travel
Have you been to an area known to be high risk for COVID-19?: No
Gender Identity and LGBTQ Identity
Gender identity: Choose not to disclose
Assigned sex at birth: Choose not to disclose

PULLIAM, Viktoriya (id #6945, dob: 12/06/1989)

Sexual orientation: Choose not to disclose

Surgical History

Reviewed Surgical History

GYN History

Reviewed GYN History

Obstetric History

Reviewed Obstetric History

Past Medical History

Reviewed Past Medical History
Anxiety Disorder: **Y**
Head Trauma/Injury: **Y**
Headaches: **Y**

Screening

Name	Score	Notes
PHQ-2/PHQ-9	8 (for the PHQ-9), Finding: Positive	
GAD-7	2	

HPI

This is a pleasant 31-year-old lady with neck pain over her posterior neck accompanied by tingling in her left arm diffusely. The tingling in the left arm is not accompanied by pain but does occur with changes in neck position. The tingling does not follow any particular peripheral nerve or dermatomal pattern. It is only in the left arm and not the right. She denies any changes in strength in the left arm.
In the past she has tried gabapentin for this but it caused severe nightmares. We recently performed a cervical epidural steroid injection with no relief or change in either pain in the neck or tingling in the left arm.
This tingling dates back to one of her car accidents.
She has never tried a sodium channel blocker to see if this would manage the tingling.
We do not have a copy of her Oregon cervical spine MRI but asked her to sign a release for one.

The results of their depression and anxiety screening tests were normal and no action is needed at this time for her mild depression.

I spent 20 minutes with this patient which consisted of chart review, patient interview and examination, documentation and coordination of care all on the same day. Time is the basis of this E & M CPT code.

ROS

Constitutional: Constitutional: no fever or night sweats.

ENMT: Nose: no frequent nosebleeds. Mouth/Throat: no bleeding gums.

Cardiovascular: Cardiovascular: no palpitations.

Respiratory: Respiratory: no coughing up blood.

Gastrointestinal: Gastrointestinal: not vomiting blood.

Musculoskeletal: Musculoskeletal: **neck pain**.

Integumentary: Skin: no jaundice or rashes.

Neurologic: Neurologic: no seizures or loss of consciousness and **numbness**.

Psychiatric: Psych: no depression, hallucinations, or suicidal thoughts.

Hematologic/Lymphatic: Hematologic/Lymphatic no bruising or excessive bleeding.

Allergic/Immunologic: Allergy/Immunologic: no itching or hives.

Physical Exam

Patient is a 31-year-old female.

Chaperone: Chaperone: offered and declined.

Constitutional: General Appearance: healthy-appearing, well-nourished, and well-developed. Level of Distress: NAD. Ambulation: ambulating normally.

Psychiatric: Insight: good judgement. Mental Status: normal mood and affect and active and alert. Orientation:

PULLIAM, Viktoriya (id #6945, dob: 12/06/1989)

to time, place, and person. Memory: recent memory normal and remote memory normal.

Head: Head: normocephalic and atraumatic; **non-tender occipital nerves**.

Eyes: Lids and Conjunctivae: non-injected and no discharge. Pupils: PERRLA. EOM: EOMI. Sclerae: non-icteric.

ENMT: Nose: no lesions on external nose or nasal discharge. Lips, Teeth, and Gums: no bleeding gums.

Lungs: Respiratory effort: no dyspnea.

Neurologic: Cranial Nerves: grossly intact. Sensation: grossly intact (**to light touch of the upper extremities**). Hoffmans Cervical Spine Reflex Left hand Hoffman's normal (-) and Right hand Hoffman's normal (-). ATHENA Cervical Spine Strength **Symmetric and normal strength deltoids, triceps, biceps, wrist flexion and extension and grip**.

Skin: Inspection and palpation: good turgor and no jaundice.

Back: Thoracolumbar Appearance: **normal posture with negative Spurling's in neutral and tilted postures, non-tender cervical spinous processes, negative cervical facet loading signs.**.

Assessment / Plan

Her neck pain got no better after her cervical epidural steroid injection and her exam is not very enlightening today.

With her description of numbness and tingling over her whole arm, not just in a dermatome or peripheral nerve pattern, one would be more suspicious of a brachial plexus injury.

1. Chronic neck pain
M54.2: Cervicalgia

2. Paresthesia of upper limb
R20.2: Paresthesia of skin
- oxcarbazepine 300 mg tablet - 1-2 po q hs Qty: 60 tablet(s) Refills: 0 Pharmacy: WALGREENS DRUG STORE #07928

3. Depression screening -
The results of their depression and anxiety screening tests were normal and no action is needed at this time for only mild depression.
Z13.31: Encounter for screening for depression

Return to Office

- John L. Mansell, MD for Follow Up at WPI-Gillette on 09/23/2021 at 01:00 PM

Encounter Sign-Off

Encounter signed-off by John L. Mansell, MD, 08/12/2021.

Encounter performed and documented by John L. Mansell, MD
Encounter reviewed & signed by John L. Mansell, MD on 08/12/2021 at 5:19pm

PULLIAM, Viktoriya (id #6945, dob: 12/06/1989)

Encounter Date: 06/24/2021

Patient

Name	PULLIAM, VIKTORIYA (31yo, F) ID# 6945	**Appt. Date/Time**	06/24/2021 03:45PM
DOB	12/06/1989	**Service Dept.**	WPI-Gillette
Provider	JOHN L. MANSELL, MD		
Insurance	Med Primary: *SELF PAY* Prescription: CVS|CAREMARK - Member is eligible. details		

Chief Complaint

neck and shoulder pain

Patient's Care Team

Referring Provider: JUSTIN MERRYMAN DC: 201 W LAKEWAY RD STE 211, GILLETTE, WY 82718, Ph (307) 217-2323, Fax (307) 228-2184 NPI: 1790227866
Primary Care Provider: AMY HAWK APRN: 501 S BURMA AVE, GILLETTE, WY 82716, Ph (307) 688-3535, Fax (307) 688-7916

Patient's Pharmacies

WALGREENS DRUG STORE #07928 (ERX): 2000 S DOUGLAS HWY, GILLETTE, WY 82718, Ph (307) 682-4517, Fax (307) 682-4563

Vitals

10/29/2021 02:16 pm

Ht: 5 ft 6 in

Allergies

Allergies not reviewed (last reviewed 04/28/2021)

PENICILLINS

Medications

Reviewed Medications

acyclovir 5 % topical ointment APPLY TOPICALLY TO THE AFFECTED AREA 6 TIMES DAILY FOR 7 DAYS	07/23/21	filled
cabergoline 0.5 mg tablet TAKE 1 TABLET BY MOUTH EVERY DAY	08/18/21	filled
escitalopram 20 mg tablet TAKE 1 TABLET BY MOUTH EVERY DAY	10/11/21	filled
methylPREDNISolone 4 mg tablets in a dose pack FOLLOW PACKAGE DIRECTIONS	07/23/21	filled
OXcarbazepine 300 mg tablet TAKE 1 TO 2 TABLETS BY MOUTH AT BEDTIME	08/12/21	filled
prednisoLONE acetate 1 % eye drops,suspension SHAKE LIQUID AND INSTILL 1 DROP IN BOTH EYES THREE TIMES DAILY	07/23/21	filled
valACYclovir 1 gram tablet TAKE 1 TABLET BY MOUTH THREE TIMES DAILY X 7 DAYS FOR OUTBREAKS/PAINFUL LESION	07/23/21	filled

Problems

PULLIAM, Viktoriya (id #6945, dob: 12/06/1989)

Reviewed Problems
No known problems

Family History

Reviewed Family History

Unspecified Relation	- Family history of alcoholism - Grandfather
	- Diabetes mellitus - Grandmother
	- Family history of cancer - Grandmother- ovarian , brain ca
Brother	- Family history of substance abuse - Illegal Drug Abuse
Father	- Heart disease
	- Hypertensive disorder

Social History

Reviewed Social History
Other
Live alone or with others?: with others
Education and Occupation
Are you currently employed?: Yes
Substance Use
Do you or have you ever smoked tobacco?: Former smoker
Do you or have you ever used smokeless tobacco?: Never used smokeless tobacco
How much tobacco do you chew?: none
What was the date of your most recent tobacco screening?: 09/23/2021
Do you use any illicit or recreational drugs?: No
What is your level of caffeine consumption?: Moderate
Public Health and Travel
Have you been to an area known to be high risk for COVID-19?: No
Gender Identity and LGBTQ Identity
Gender identity: Choose not to disclose
Assigned sex at birth: Choose not to disclose
Sexual orientation: Choose not to disclose

Surgical History

Surgical History not reviewed (last reviewed 04/28/2021)

GYN History

GYN History not reviewed (last reviewed 04/28/2021)

Obstetric History

Obstetric History not reviewed (last reviewed 04/28/2021)

Past Medical History

Past Medical History not reviewed (last reviewed 04/28/2021)
Anxiety Disorder: **Y**
Head Trauma/Injury: **Y**
Headaches: **Y**

Screening

None recorded.

HPI

This is a pleasant 31 year old lady with a history of bilateral lower neck and shoulder pain referred by Dr. Merryman for a trial of a cervical epidural steroid injection.

Risks of this were reviewed with them including bleeding, infection, nerve damage, spinal cord damage, paraplegia, quadriplegia, permanent incontinence and death. They are taking no anticoagulant medications and have a review of systems negative for coagulopathic symptoms, no easy bruising, gingival bleeding or epistaxis. They are afebrile with no infectious disease symptoms.

Informed consent was obtained.

ROS

Constitutional: Constitutional: no fever or night sweats.

ENMT: Nose: no frequent nosebleeds. Mouth/Throat: no bleeding gums.

PULLIAM, Viktoriya (id #6945, dob: 12/06/1989)

Hematologic/Lymphatic: Hematologic/Lymphatic no bruising or excessive bleeding.

Physical Exam

None recorded.

Procedure Documentation

Cervical Epidural Steroid Injection:

Risks of this were reviewed with her including bleeding, infection, nerve damage, spinal cord damage, paraplegia, quadriplegia, permanent incontinence and death. She is taking no blood thinner medications and has a review of systems negative for coagulopathic symptoms. She is afebrile with no recent infectious disease symptoms. Informed consent was obtained.

In a prone position on the fluoroscopy table after a timeout was observed her upper back and posterior neck or prepped widely with Betadine and draped in the usual sterile fashion. Using a C-arm fluoroscopic unit the C7 T-1 interlaminar space was visualized and through topical cold spray and lidocaine infiltration a 22 gauge Tuohy needle was walked off inferior aspect of the left C7 lamina and into the epidural space with loss of resistance technique using 2 mL of Omnipaque 240 contrast which yielded an immediate epidurogram. Following another negative aspirate for milliliters comprised of 3 mL or 30 mg of dexamethasone and 1 mL of 0.25% bupivacaine (both preservative free) was injected displacing the previously noted dye pattern. The needle was withdrawn intact. A Band-Aid was placed on the site.

A list of side effects, complications and their symptoms were reviewed with her and she was instructed to contact us should any of these give her concern. The delayed onset of steroid effect with transient exacerbation of symptoms was explained to them as well and they were discharged without incident.

Assessment / Plan

The procedure went smoothly and she tolerated it well.

1. Cervical radiculitis
M54.12: Radiculopathy, cervical region

Return to Office

Patient will return to the office as needed.

Encounter Sign-Off

Encounter signed-off by John L. Mansell, MD, 10/30/2021.

Encounter performed and documented by John L. Mansell, MD
Encounter reviewed & signed by John L. Mansell, MD on 10/30/2021 at 8:19am

PULLIAM, Viktoriya (id #6945, dob: 12/06/1989)

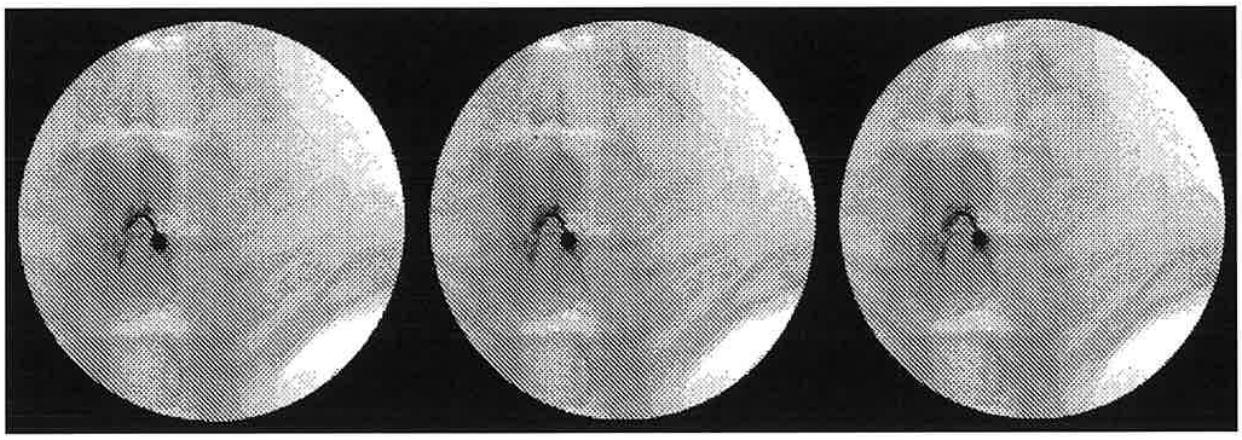

PULLIAM, Viktoriya (id #6945, dob: 12/06/1989)

Encounter Date: 04/28/2021

Patient

Name	PULLIAM, VIKTORIYA (31yo, F) ID# 6945	**Appt. Date/Time**	04/28/2021 01:30PM
DOB	12/06/1989	**Service Dept.**	WPI-Gillette
Provider	JOHN L. MANSELL, MD		
Insurance	Med Primary: *SELF PAY* Prescription: CVS|CAREMARK - Member is eligible. details		

Chief Complaint

low back pain

Patient's Pharmacies

WALGREENS DRUG STORE #07928 (ERX): 2000 S DOUGLAS HWY, GILLETTE, WY 82718, Ph (307) 682-4517, Fax (307) 682-4563

Vitals

Ht:	5 ft 6 in Stated 04/28/2021 01:37 pm	**Wt:**	157 lbs Stated 04/28/2021 01:37 pm	**BMI:**	25.3 04/28/2021 01:37 pm
HR:	81 04/28/2021 01:37 pm	**BP:**	117/75 sitting L arm 04/28/2021 01:37 pm	**T:**	97.7 F° temporal artery 04/28/2021 01:38 pm
O2Sat:	97% Room Air at Rest 04/28/2021 01:38 pm	**Pain Scale:**	4 04/28/2021 01:38 pm		

Allergies

Reviewed Allergies

PENICILLINS

Medications

Reviewed Medications

escitalopram 20 mg tablet TAKE 1 TABLET BY MOUTH EVERY DAY	04/21/21	filled
HYDROcodone 5 mg-acetaminophen 325 mg tablet 1 po up to BID prn pain	04/28/21	prescribed
predniSONE 10 mg tablet 1 po q day for 5 days	04/28/21	prescribed

Problems

Reviewed Problems
No known problems

Family History

Reviewed Family History

PULLIAM, Viktoriya (id #6945, dob: 12/06/1989)

Unspecified Relation	- Family history of alcoholism - Grandfather
	- Diabetes mellitus - Grandmother
	- Family history of cancer - Grandmother- ovarian , brain ca
Brother	- Family history of substance abuse - Illegal Drug Abuse
Father	- Heart disease
	- Hypertensive disorder

Social History

Reviewed Social History
Education and Occupation
Are you currently employed?: Yes
Substance Use
Do you or have you ever smoked tobacco?: Former smoker
Do you or have you ever used smokeless tobacco?: Never used smokeless tobacco
How much tobacco do you chew?: none
What was the date of your most recent tobacco screening?: 04/28/2021
Do you use any illicit or recreational drugs?: No
What is your level of caffeine consumption?: Moderate
Public Health and Travel
Have you been to an area known to be high risk for COVID-19?: No
Gender Identity and LGBTQ Identity
Gender identity: Choose not to disclose
Assigned sex at birth: Choose not to disclose
Sexual orientation: Choose not to disclose

Surgical History

Reviewed Surgical History

GYN History

Reviewed GYN History

Obstetric History

Reviewed Obstetric History

Past Medical History

Reviewed Past Medical History
Anxiety Disorder: **Y**
Head Trauma/Injury: **Y**
Headaches: **Y**

Screening

None recorded.

HPI

This is a pleasant 31 year old lady with a history of bilateral lower back pain referred by Dr. Merryman for bilateral L3 to S1 rhizotomies.

Risks of this were reviewed with them including bleeding, infection, nerve damage, spinal cord damage, paraplegia, quadriplegia, permanent incontinence and death. They are taking no anticoagulant medications and have a review of systems negative for coagulopathic symptoms, no easy bruising, gingival bleeding or epistaxis. They are afebrile with no infectious disease symptoms.

Informed consent was obtained.

ROS

Constitutional: Constitutional: no fever or night sweats.

ENMT: Nose: no frequent nosebleeds. Mouth/Throat: no bleeding gums.

Hematologic/Lymphatic: Hematologic/Lymphatic no bruising or excessive bleeding.

Physical Exam

None recorded.

PULLIAM, Viktoriya (id #6945, dob: 12/06/1989)

Procedure Documentation

Lumbar Radiofrequency Ablations of Medial Branch Nerves:
Bilateral L3 to S1 Radiofrequency Ablations of Medial Branch Nerves

Risks of this were reviewed with her including bleeding, infection, nerve damage, spinal cord damage, paraplegia, quadriplegia, permanent incontinence and death. She is taking no blood thinner medications and has a review of systems negative for coagulopathic symptoms. She is afebrile with no recent infectious disease symptoms. Informed consent was obtained.
In a prone position on the fluoroscopy table after a timeout was observed her back was prepped widely with Betadine and draped in the usual sterile fashion. Using a C-arm telescopic unit and an AP view the transverse processes bilaterally at L3, L4 and L5 as well as the sacral alae were visualized and through topical cold spray and an acupuncture needle insertion technique 18gauge radiofrequency needles were placed on the superior aspect of the medial third of each of these locations at these levels bilaterally and incremental moves were made until successful stimulation was achieved at 50 Hz at less than .5 V with negative motor stimulation at 2 Hz at triple the sensory threshold. After this was accomplished 2.5 mL of 0.75% bupivacaine with 4 mg/mL of Depo-Medrol admixed was injected to each needle and we waited five minutes before performing ablations at 80°C for 75 seconds. Two 120° clockwise turns were performed within ablation after each turn for a total of three ablations at each level. All needles were withdrawn intact. Band-Aids were placed on the sites.

She was returned to the postprocedure observation area where she appeared to tolerate the procedure well. A list of side effects, complications and their symptoms were reviewed with her and she was instructed to contact us should any of these give them concern. She tolerated the procedure well and was discharged without incident.

He was returned to the postprocedure observation area where he appeared to tolerate the procedure well. A list of side effects, complications and their symptoms were reviewed with him and he was instructed to contact us should any of these give him concern. The delayed onset of steroid effect with transit exacerbation of symptoms was explained to him as well and he was discharged without incident.

Assessment / Plan

The procedure went smoothly and she tolerated it well.

1. Lumbosacral spondylosis without myelopathy
M47.817: Spondylosis without myelopathy or radiculopathy, lumbosacral region

- hydrocodone 5 mg-acetaminophen 325 mg tablet - 1 po up to BID prn pain Qty: 14 tablet(s) Refills: 0 Pharmacy: WALGREENS DRUG STORE #07928
- prednisone 10 mg tablet - 1 po q day for 5 days Qty: 5 tablet(s) Refills: 0 Pharmacy: WALGREENS DRUG STORE #07928

Return to Office

None recorded.

Encounter Sign-Off

Encounter signed-off by John L. Mansell, MD, 04/28/2021.

Encounter performed and documented by John L. Mansell, MD
Encounter reviewed & signed by John L. Mansell, MD on 04/28/2021 at 3:11pm

PULLIAM, Viktoriya (id #6945, dob: 12/06/1989)

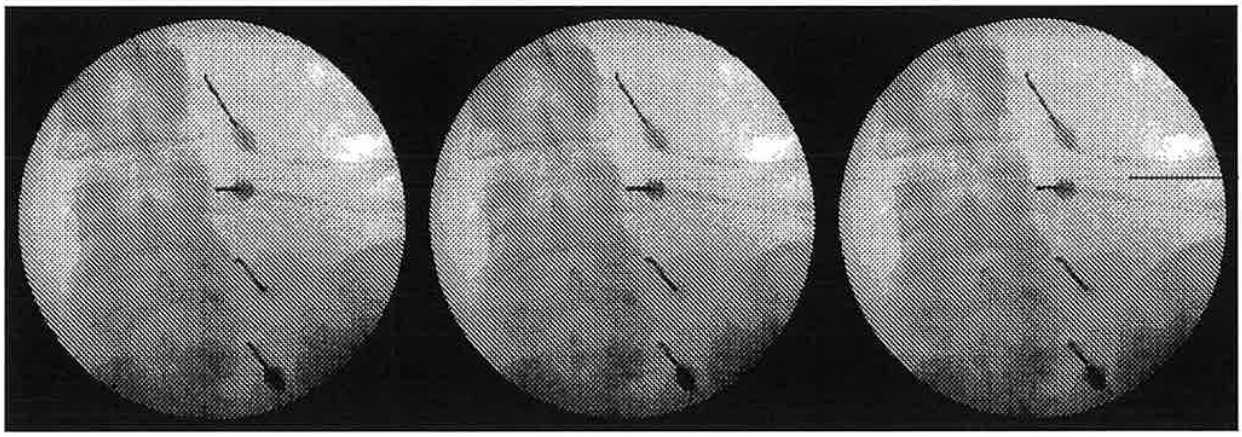

PULLIAM, Viktoriya (id #6945, dob: 12/06/1989)

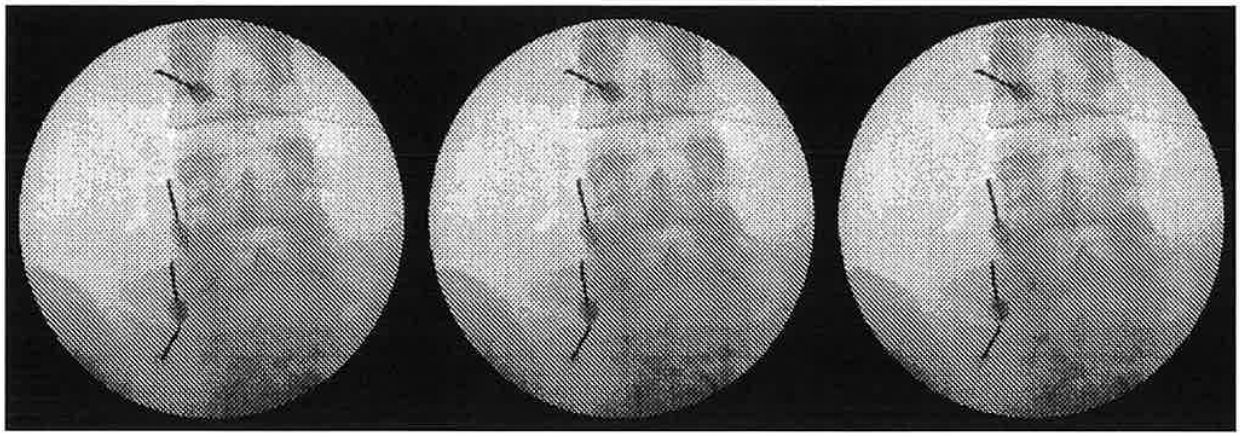

PULLIAM, Viktoriya (id #6945, dob: 12/06/1989)

Encounter Date: 04/14/2021

Patient

Name	PULLIAM, VIKTORIYA (31yo, F) ID# 6945	**Appt. Date/Time**	04/14/2021 03:30PM
DOB	12/06/1989	**Service Dept.**	WPI-Gillette
Provider	JOHN L. MANSELL, MD		
Insurance	Med Primary: *SELF PAY* Prescription: CVS|CAREMARK - Member is eligible. details		

Chief Complaint

Scheduled Procedure

low back pain

Vitals

Ht:	5 ft 6 in Stated 04/14/2021 03:48 pm	**Wt:**	157 lbs Stated 04/14/2021 03:49 pm	**BMI:**	25.3 04/14/2021 03:49 pm
HR:	67 04/14/2021 03:49 pm	**BP:**	105/64 sitting L arm 04/14/2021 03:49 pm	**T:**	97.5 F° temporal artery 04/14/2021 03:49 pm
O2Sat:	96% Room Air at Rest 04/14/2021 03:49 pm	**Pain Scale:**	3 04/14/2021 03:49 pm		

Allergies

Reviewed Allergies

PENICILLINS

Medications

Reviewed Medications

escitalopram 20 mg tablet 03/12/21 filled
TAKE 1 TABLET BY MOUTH EVERY DAY

Problems

Reviewed Problems
No known problems

Family History

Reviewed Family History

Unspecified Relation	- Family history of alcoholism - Grandfather
	- Diabetes mellitus - Grandmother
	- Family history of cancer - Grandmother- ovarian , brain ca
Brother	- Family history of substance abuse - Illegal Drug Abuse
Father	- Heart disease
	- Hypertensive disorder

Social History

Reviewed Social History
Education and Occupation
Are you currently employed?: Yes

PULLIAM, Viktoriya (id #6945, dob: 12/06/1989)

Substance Use
Do you or have you ever smoked tobacco?: Former smoker
Do you or have you ever used smokeless tobacco?: Never used smokeless tobacco
How much tobacco do you chew?: none
What was the date of your most recent tobacco screening?: 04/14/2021
Do you use any illicit or recreational drugs?: No
What is your level of caffeine consumption?: Moderate
Public Health and Travel
Have you been to an area known to be high risk for COVID-19?: No
Gender Identity and LGBTQ Identity
Gender identity: Choose not to disclose
Assigned sex at birth: Choose not to disclose
Sexual orientation: Choose not to disclose

Surgical History

Reviewed Surgical History

GYN History

Reviewed GYN History

Obstetric History

Reviewed Obstetric History

Past Medical History

Reviewed Past Medical History
Anxiety Disorder: **Y**
Head Trauma/Injury: **Y**
Headaches: **Y**

Screening

None recorded.

HPI

This is a pleasant 31 year old lady with a history of bilateral lower back pain referred by Dr. Merryman for a trial of bilateral L3 to S1 lumbar medial branch blocks.

Risks of this were reviewed with them including bleeding, infection, nerve damage, spinal cord damage, paraplegia, quadriplegia, permanent incontinence and death. They are taking no anticoagulant medications and have a review of systems negative for coagulopathic symptoms, no easy bruising, gingival bleeding or epistaxis. They are afebrile with no infectious disease symptoms.

Informed consent was obtained.

ROS

Constitutional: Constitutional: no fever or night sweats.

ENMT: Nose: no frequent nosebleeds. Mouth/Throat: no bleeding gums.

Hematologic/Lymphatic: Hematologic/Lymphatic no bruising or excessive bleeding.

Physical Exam

None recorded.

Procedure Documentation

Lumbar Medial Branch Blocks:
Bilateral L3 to S1 Lumbar Medial Branch Blocks

Risks of lumbar medial branch blocks were reviewed with the patient including bleeding, infection, nerve damage, spinal cord damage, paraplegic, quadriplegic, permanent incontinence and death. The patient is taking no anticoagulant medications and has a review of systems negative for coagulopathic symptoms including bleeding, infection, nerve damage, spinal cord damage, paraplegic, quadriplegic, permanent incontinence and death. They are afebrile with no recent infectious disease symptoms. Informed consent was obtained.

in a prone position on the fluoroscopy table after a timeout was performed the transverse processes from L3 to S1 bilaterally were visualized fluoroscopically and after prepping and draping in the usual sterile fashion through topical cold spray and an acupuncture needle insertion technique a 25gauge 3.5" needle was placed down to the superior aspect of the medial third of each of these transverse processes bilaterally at these levels. Following a negative aspirate on each needle 1 mL of Omnipaque 200 contrast

was injected through each needle yielding a supra-cortical pattern of spread. Following another negative aspirate 1 mL of 0.75% bupivacaine was injected through each needle displacing the previously noted dye patterns. The needles were withdrawn intact. Band-Aids were placed on the sites.

The patient was returned to the post-procedure observation area where after one hour they reported their pain dropped from an "3" to a "1" or "75%" better. She was sent home with a three-day pain diary as well.

A list of side effects, complications and their symptoms were reviewed with them and they were instructed to contact us should any of these give them concern. The transient nature of diagnostic blocks was explained to them as well and they were discharged without incident. They tolerated the procedure well.

Assessment / Plan

The procedure went smoothly and she tolerated it well.

1. Possible pregnancy
Z32.00: Encounter for pregnancy test, result unknown
- PREGNANCY TEST, URINE - Specimen source: Urine

2. Lumbosacral spondylosis without myelopathy
M47.817: Spondylosis without myelopathy or radiculopathy, lumbosacral region

Return to Office
None recorded.

Encounter Sign-Off
Encounter signed-off by John L. Mansell, MD, 04/14/2021.

Encounter performed and documented by John L. Mansell, MD
Encounter reviewed & signed by John L. Mansell, MD on 04/14/2021 at 5:21pm

PULLIAM, Viktoriya (id #6945, dob: 12/06/1989)

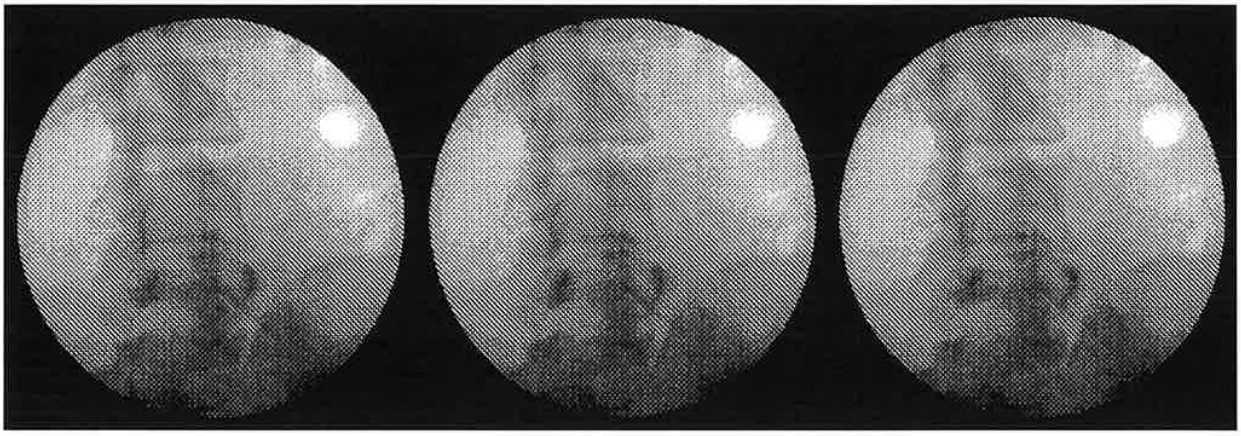

PULLIAM, Viktoriya (id #6945, dob: 12/06/1989)

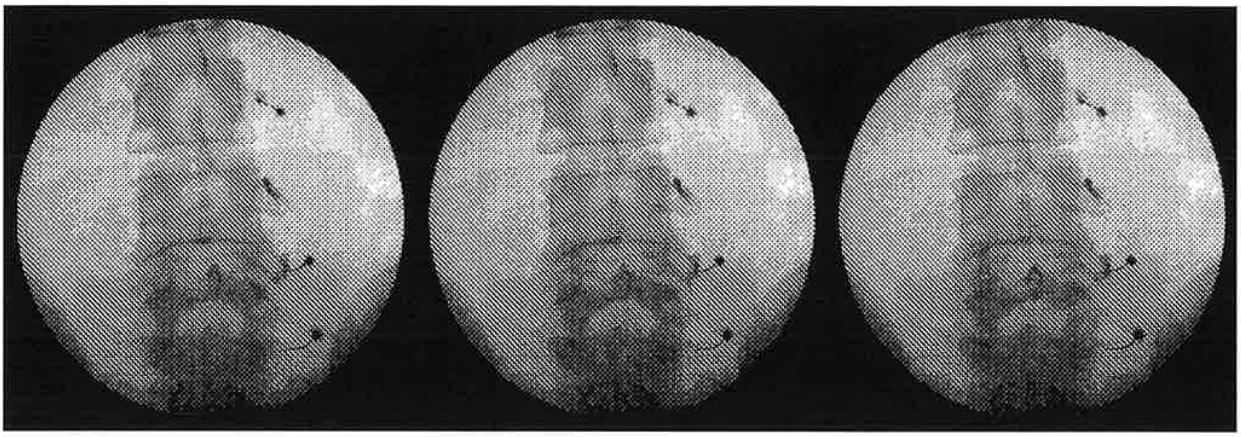

PULLIAM, Viktoriya (id #6945, dob: 12/06/1989)

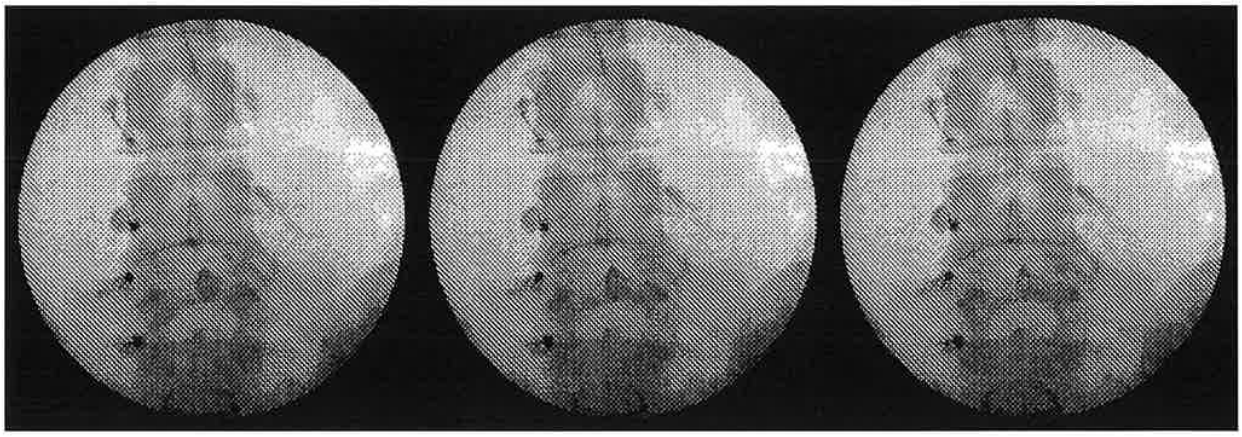

PULLIAM, Viktoriya (id #6945, dob: 12/06/1989)

Encounter Date: 04/12/2021

Patient

Name	PULLIAM, VIKTORIYA (31yo, F) ID# 6945	**Appt. Date/Time**	04/12/2021 09:30AM
DOB	12/06/1989	**Service Dept.**	WPI-Gillette
Provider	JOHN L. MANSELL, MD		
Insurance	Med Primary: *SELF PAY* Prescription: CVS|CAREMARK - Member is eligible. details		

Chief Complaint

low back pain

Vitals

04/12/2021 09:49 am

Ht: 5 ft 6 in Stated **Wt:** 157 lbs Stated **BMI:** 25.3

HR: 59

Allergies

Reviewed Allergies

PENICILLINS

Medications

Reviewed Medications

escitalopram 20 mg tablet 03/12/21 filled
TAKE 1 TABLET BY MOUTH EVERY DAY

Problems

Reviewed Problems
No known problems

Family History

Reviewed Family History

Unspecified Relation	- Family history of alcoholism - Grandfather
	- Diabetes mellitus - Grandmother
	- Family history of cancer - Grandmother- ovarian , brain ca
Brother	- Family history of substance abuse - Illegal Drug Abuse
Father	- Heart disease
	- Hypertensive disorder

Social History

Reviewed Social History
Education and Occupation
Are you currently employed?: Yes
Substance Use
Do you or have you ever smoked tobacco?: Former smoker
Do you or have you ever used smokeless tobacco?: Never used smokeless tobacco
How much tobacco do you chew?: none
What was the date of your most recent tobacco screening?: 04/14/2021
Do you use any illicit or recreational drugs?: No
What is your level of caffeine consumption?: Moderate
Public Health and Travel
Have you been to an area known to be high risk for COVID-19?: No

PULLIAM, Viktoriya (id #6945, dob: 12/06/1989)

Gender Identity and LGBTQ Identity
Gender identity: Choose not to disclose
Assigned sex at birth: Choose not to disclose
Sexual orientation: Choose not to disclose

Surgical History

Reviewed Surgical History

GYN History

Reviewed GYN History

Obstetric History

Reviewed Obstetric History

Past Medical History

Reviewed Past Medical History
Anxiety Disorder: **Y**
Head Trauma/Injury: **Y**
Headaches: **Y**

Screening

Name	Score	Notes
Opioid Risk	4	

HPI

This is a pleasant 31-year-old lady with a history of back pain that dates back to two motor vehicle accidents in November 2019 and February 2020. In the first accident she was struck from the driver side while restrained and in February 2020 she was struck on the passenger side. Since these accidents she has felt that her back pain has progressively gotten worse.

She describes a 3 inch high area of pain that spans her back with about 70% on the left side and 30% on the right which may also refer down the left lateral thigh in a 1 inch wide stripe to her knee.

Overall she apportions the pain is 90% in her back and 10% in her left leg.

She also reports pain over the lower thoracic spine that will also go down into her back on a daily basis with more severe episodes happening on average twice a week.

She describes the pain is achy with electric sensation as well as pressure, throbbing, horizontal and vertical pulling and a sense of tightness in her back.

In the last month the pain is been as severe as 8/10 and as low as 0/10.

When she gets up in the morning the pain tends to be worse for about an hour and by noon it is typically more severe. It awakens her every night.

Exacerbating factors include standing more than 5 to 10 minutes, lying in any static position more than 30 minutes, rolling over in her sleep which will awaken her with pain, stairs, straightening up at the waist which is more painful than bending forward, lifting, driving or sitting more than 10 minutes and light housework which requires frequent breaks.

Mitigating factors include lying down on her sides, leaning on other objects to take the weight off of her back or topical heat.

Associated symptoms include tingling in her legs the long drives, muscle spasms causing hip flexion as well as clicking and fine crepitance in her back. She denies any weakness or unintentional weight loss or changes in bladder or rectal control. She does say that the last year she has gained about 25 pounds.

Her most recent Pap smear was this year. She underwent an ectopic surgery in 2019 but does not feel this affected her back pain. She has taken Advil in this is helped a little bit.

I spent 45 minutes with this patient which consisted of chart review, patient interview and examination, documentation and coordination of care all on the same day. Time is the basis of this E & M CPT code.

ROS

Constitutional: Constitutional: no fever or night sweats.

Eyes: Eyes: **vision change.**

PULLIAM, Viktoriya (id #6945, dob: 12/06/1989)

ENMT: Nose: no frequent nosebleeds. Mouth/Throat: no bleeding gums.

Cardiovascular: Cardiovascular: no palpitations.

Gastrointestinal: Gastrointestinal: **nausea**, **vomiting**, and **constipation**.

Genitourinary: Genitourinary: no incontinence or hematuria.

Musculoskeletal: Musculoskeletal: **back pain**.

Integumentary: Skin: no jaundice or rashes.

Neurologic: Neurologic: no seizures or loss of consciousness and **dizziness** and **frequent or severe headaches**.

Psychiatric: Psych: no hallucinations and **suicidal thoughts**.

Hematologic/Lymphatic: Hematologic/Lymphatic no bruising or excessive bleeding.

Allergic/Immunologic: Allergy/Immunologic: no itching or hives.

Physical Exam

Patient is a 31-year-old female.

Chaperone: Chaperone: offered and declined.

Constitutional: General Appearance: healthy-appearing, well-nourished, and well-developed. Level of Distress: NAD.

Psychiatric: Insight: good judgement. Mental Status: normal mood and affect and active and alert. Orientation: to time, place, and person. Memory: recent memory normal and remote memory normal.

Head: Head: normocephalic and atraumatic.

Eyes: Lids and Conjunctivae: non-injected and no discharge. Pupils: PERRLA. EOM: EOMI. Sclerae: non-icteric.

ENMT: Nose: no lesions on external nose or nasal discharge. Lips, Teeth, and Gums: no bleeding gums. Oropharynx: moist mucous membranes.

Lungs: Respiratory effort: no dyspnea.

Cardiovascular: Pulses including femoral / pedal: radial right +2 and +1, radial left +2, posterior tibialis left: 1+ and right: 1+, and dorsalis pedis left: 1+.

Abdomen: Bowel Sounds: normal. Inspection and Palpation: soft, non-distended, and no tenderness.

Musculoskeletal:: Joints, Bones, and Muscles: no pain with log roll: left or right, no leg length discrepancy, and nontender to palpation: left greater trochanter and palpation: right greater trochanter. Extremities: no edema.

Neurologic: Cranial Nerves: grossly intact. Sensation: grossly intact. Coordination and Cerebellum: no tremor. Femoral Nerve Stretch: femoral nerve traction test negative (**bilaterally**). Lumbar / Lumbosacral Spine negative left straight leg raise and right straight leg raise. Hoffmans Lumbar Reflex Integrity Left foot Hoffman's normal (-) and Right foot Hoffman's normal (-). ATHENA Cervical Spine Strength **Symmetric and normal strength deltoids, triceps, biceps, wrist flexion and extension and grip, symmetric and low normal strength with hip flexion, extension, abduction and adduction, knee flexion and extension as well as dorsiflexion plantarflexion at the ankles.**.

Skin: Inspection and palpation: good turgor and no jaundice.

Back: Thoracolumbar Appearance: **normal lumbar lordosis with increased pain with lumbar extension and lumbar axial rotation, tender over the L3, L4 and L5 spinous processes but not the PSIS bilaterally, normal lumbar muscle tone with no palpable trigger points.**.

Assessment / Plan

Palpation over the L3, L4 and L5 spinous processes as well as lumbar extension were the most provocative exam maneuver and caused concordant pain. For this reason I recommended a trial of medial branch blocks at these levels.

1. Chronic pain syndrome
G89.4: Chronic pain syndrome
- DRUG SCREEN, URINE - Specimen source: Urine

2. Lumbosacral spondylosis without myelopathy

PULLIAM, Viktoriya (id #6945, dob: 12/06/1989)

M47.817: Spondylosis without myelopathy or radiculopathy, lumbosacral region

DRUG SCREEN, URINE

- Results:
  - **THC: negative**
  - **Temperature: 94 degrees**
  - **OPI: negative**
  - **AMP: negative**
  - **MET: negative**
  - **PCP: negative**
  - **BZO: negative**
  - **BAR: negative**
  - **MDMA: negative**
  - **MTD: negative**
  - **OXY: negative**
  - **TCA: negative**
  - **BUP: negative**
  - **EDDP: negative**
  - **COC: negative**

Return to Office

None recorded.

Encounter Sign-Off

Encounter signed-off by John L. Mansell, MD, 04/14/2021.

Encounter performed and documented by John L. Mansell, MD
Encounter reviewed & signed by John L. Mansell, MD on 04/14/2021 at 5:24pm

PULLIAM, Viktoriya (id #6945, dob: 12/06/1989)

A WYOMING PAIN CLINIC, P.C.

printed 01/08/2026 01:45 PM

Billing Address

PO BOX 16066
BELFAST, ME 04915-4055
billing phone: (307) 299-7622

Group TIN: 474229219

GUARANTOR NAME AND ADDRESS: VIKTORIYA PULLIAM

PATIENT # 6945

PATIENT NAME: VIKTORIYA PULLIAM

DOB: 12/06/1989

HOME TELEPHONE: (503) 208-1326

Billing Summary

Expand all claim details

Claim ID	Procedure	Date of Service	Pos. Date	Type	Reason	Plan	Supervising Provider	Ins. 1	Ins. 2	Patient
Claim ID 19507										
19507	80305	04/12/2021	04/20/2021	**CHARGE**	80305	PATIENT	JOHN MANSELL			$30.00
19507	80305	04/12/2021	04/21/2021	PAYMENT	MC/VISA	PATIENT	JOHN MANSELL			
							OUTSTANDING	$0.00	$0.00	$0.00
19507	99204	04/12/2021	04/20/2021	**CHARGE**	99204	PATIENT	JOHN MANSELL			$365.00
19507	99204	04/12/2021	04/21/2021	PAYMENT	MC/VISA	PATIENT	JOHN MANSELL			
							OUTSTANDING	$0.00	$0.00	$0.00
Claim ID 19550										
19550	64493,50	04/14/2021	04/30/2021	**CHARGE**	64493,50	PATIENT	JOHN MANSELL			$659.00
19550	64493,50	04/14/2021	04/30/2021	PAYMENT	MC/VISA	PATIENT	JOHN MANSELL			
							OUTSTANDING	$0.00	$0.00	$0.00
19550	64494,50	04/14/2021	04/30/2021	**CHARGE**	64494,50	PATIENT	JOHN MANSELL			$203.00
19550	64494,50	04/14/2021	04/30/2021	PAYMENT	MC/VISA	PATIENT	JOHN MANSELL			
							OUTSTANDING	$0.00	$0.00	$0.00
19550	64495,50	04/14/2021	04/30/2021	**CHARGE**	64495,50	PATIENT	JOHN MANSELL			$135.00
19550	64495,50	04/14/2021	04/30/2021	PAYMENT	MC/VISA	PATIENT	JOHN MANSELL			
							OUTSTANDING	$0.00	$0.00	$0.00
19550	Q9966	04/14/2021	04/30/2021	**CHARGE**	Q9966	PATIENT	JOHN MANSELL			$6.00
19550	Q9966	04/14/2021	04/30/2021	PAYMENT	MC/VISA	PATIENT	JOHN MANSELL			
							OUTSTANDING	$0.00	$0.00	$0.00
Claim ID 19627										
19627	64635,50	04/28/2021	04/30/2021	**CHARGE**	64635,50	PATIENT	JOHN MANSELL			$1,212.00
19627	64635,50	04/28/2021	04/30/2021	PAYMENT	MC/VISA	PATIENT	JOHN MANSELL			
19627	64635,50	04/28/2021	04/30/2021	PAYMENT	MC/VISA	PATIENT	JOHN MANSELL			
19627	64635,50	04/28/2021	04/30/2021	PAYMENT	MC/VISA	PATIENT	JOHN MANSELL			

A WYOMING PAIN CLINIC, P.C. • 3100 W Lakeway Rd, Gillette WY 82718-6373

PULLIAM, Viktoriya (id #6945, dob: 12/06/1989)

19627	64635,50	04/28/2021	04/30/2021	PAYMENT	MC/VISA	PATIENT	JOHN MANSELL			$-55.00
19627	64635,50	04/28/2021	05/07/2021	ADJUSTMENT	OTHER	PATIENT	JOHN MANSELL			
							OUTSTANDING	$0.00	$0.00	$0.00
19627	64636,50	04/28/2021	04/30/2021	CHARGE	64636,50	PATIENT	JOHN MANSELL			$790.00
19627	64636,50	04/28/2021	05/07/2021	ADJUSTMENT	OTHER	PATIENT	JOHN MANSELL			
							OUTSTANDING	$0.00	$0.00	$0.00
19627	J1040	04/28/2021	04/30/2021	CHARGE	J1040	PATIENT	JOHN MANSELL			$25.00
19627	J1040	04/28/2021	05/07/2021	ADJUSTMENT	OTHER	PATIENT	JOHN MANSELL			
							OUTSTANDING	$0.00	$0.00	$0.00
Claim ID 20688										
20688	99213	08/12/2021	08/17/2021	CHARGE	99213	PATIENT	JOHN MANSELL			$114.00
20688	99213	08/12/2021	08/18/2021	PAYMENT	UNAPPLIED	PATIENT	JOHN MANSELL			
							OUTSTANDING	$0.00	$0.00	$0.00
20688	99484	08/12/2021	08/17/2021	CHARGE	99484	PATIENT	JOHN MANSELL			$80.00
20688	99484	08/12/2021	08/18/2021	PAYMENT	UNAPPLIED	PATIENT	JOHN MANSELL			$-36.00
20688	99484	08/12/2021	09/21/2021	ADJUSTMENT	OTHER	PATIENT	JOHN MANSELL			
							OUTSTANDING	$0.00	$0.00	$0.00
Claim ID 21096										
21096	99213	09/23/2021	09/28/2021	CHARGE	99213	PATIENT	JOHN MANSELL			$114.00
21096	99213	09/23/2021	12/01/2021	PAYMENT	MC/VISA **********3565	PATIENT	JOHN MANSELL			
							OUTSTANDING	$0.00	$0.00	$0.00
Claim ID 26945										
26945	00731,AA	07/26/2023	07/31/2023	CHARGE	00731,AA		JOHN MANSELL	$1,140.00		
26945	00731,AA	07/26/2023	08/30/2023	PAYMENT	ACH **********6129		JOHN MANSELL			
							OUTSTANDING	$0.00	$0.00	$0.00
Claim ID 28634										
28634	99212	01/04/2024	01/08/2024	CHARGE	99212		JOHN MANSELL	$129.00		
28634	99212	01/04/2024	01/18/2024	TRANSFERIN	DEDUCTIBLE	PATIENT	JOHN MANSELL			$129.00
28634	99212	01/04/2024	03/19/2024	PAYMENT	AMEX **********0624	PATIENT	JOHN MANSELL			
							OUTSTANDING			
							TOTAL CHARGE OUTSTANDING AS OF 01/08/2026			